

# Evaluation of the Patient

## A. History and Physical Examination

DAVID B. ROBINSON, MD, MSc, FRCPC  
HANI S. EL-GABALAWY, MD, FRCPC

- The patient history and physical examination form the basis of diagnosis and monitoring the course of rheumatic and musculoskeletal diseases.
- Attention is focused on signs and symptoms of both joint and extra-articular features.
- The joint examination must include pattern, range of motion, signs of inflammation, stability, weakness, and deformity.

Musculoskeletal complaints are among the most common problems in clinical medicine. It is therefore important that all physicians are able to conduct a basic screening evaluation that identifies the presence of pathology or dysfunction of musculoskeletal structures.

### RHEUMATOLOGICAL HISTORY

A thoughtful and detailed history plays a critical role in determining the nature of the complaint and helps to focus the clinical evaluation (1). The history should be structured to answer specific questions.

#### Questions for the Clinician to Address

1. Is the problem regional or generalized, symmetric or asymmetric, peripheral or central?
2. Is it an acute, subacute, or chronic problem? Is it progressive?
3. Do the symptoms suggest inflammation or damage to musculoskeletal structures?
4. Is there evidence of a systemic process? Are there associated extra-articular features?
5. Is there an underlying medical disorder which may predispose to a specific rheumatologic problem?
6. Has there been functional loss and disability?
7. Is there a family history of a similar or related problem?

#### Location and Symmetry

The location of a musculoskeletal problem is often the most important clue in identifying the specific cause. Musculoskeletal problems can broadly be categorized as regional or generalized, although there is often considerable overlap between these two categories. Regional syndromes typically affect a single joint or periarticular structure, or an entire extremity or body region. A regional pain syndrome can be on a referred basis, and have little to do with the area where the pain is experienced. Joints both immediately above and below the painful area should be routinely examined for pathology.

Specific arthropathies have a predilection for involving specific joint areas (2). Involvement of the wrists and the proximal small joints of the hands and feet is an important feature of rheumatoid arthritis (RA). In contrast, psoriatic arthritis (PsA) often involves the distal joints of the hands and feet. An acutely painful and swollen great toe is most likely caused by a gouty attack. An important aspect of the articular pattern of involvement is symmetry. Rheumatoid arthritis tends to involve joint groups symmetrically, whereas the seronegative spondyloarthropathies and osteoarthritis (OA) tend to be asymmetrical in their articular patterns.

#### Onset and Chronology

The mode of onset and evolution of musculoskeletal symptoms over time is very helpful in establishing a diagnosis. For most chronic arthropathies such as RA, the onset is typically subacute, occurring over weeks to

months rather than hours to days. Attacks of gout and septic arthritis, on the other hand, have an acute onset, reaching a crescendo within hours. The pain of fibromyalgia is often reported as being present for years with episodic exacerbations. A temporally associated traumatic event or history of repetitive use of a joint can be a particularly good clue to diagnosing a regional musculoskeletal syndrome.

## Inflammation and Weakness

Articular pain and swelling can be on an inflammatory or non-inflammatory basis. When intra-articular inflammation is present, the process involves the synovial membrane, and is termed *synovitis*. The swelling is usually due to accumulation of fluid in the articular cavity and/or infiltration and enlargement of the synovium. Pain and swelling associated with the presence of synovitis often occur at rest, whereas in degenerative disorders such as OA, these symptoms become more evident with joint use. In the presence of synovitis, the patient may also complain of difficulty moving the joints after a period of immobility, a symptom referred to as *stiffness*. In inflammatory disorders such as RA, this stiffness is most evident in the early morning. Indeed, the duration of morning stiffness, typically established by asking the patient, “How long does it take you before you are moving as well as you are going to move for the day?” is a semiquantitative measure of the degree of articular inflammation.

Complaints of limitation in joint motion, deformity, and joint instability are usually caused by damage to articular and periarticular structures. The patient should be carefully questioned to establish the circumstances around which these symptoms were initiated, and the types of movements that aggravate them.

Patients with musculoskeletal pathology often complain of muscle weakness. This feeling of weakness may be associated with pain, stiffness, and, in some cases, paresthesia or other neurological symptoms. Generalized weakness may be in response to pain from articular or periarticular inflammation, as in the case of RA and polymyalgia rheumatica. Alternatively, weakness may be caused by a primary neuropathic or myopathic process. In the case of myopathies, the weakness is typically symmetrical and involves proximal muscles most severely, whereas neuropathies more commonly affect the distal musculature.

## Systemic and Extra-Articular Features

Constitutional symptoms of fatigue, weight loss, anorexia, and low grade fever can be associated with any systemic inflammatory process, and their presence is an

important diagnostic clue. In addition, systemic rheumatic diseases are commonly associated with nonarticular features that are of value in diagnosis. For example, a history of recent genitourinary symptoms in association with lower extremity asymmetric oligoarthritis is highly suggestive of reactive arthritis, whereas this same articular pattern in association with recurrent abdominal pain and bloody diarrhea is more suggestive of the arthropathy of inflammatory bowel disease. It is thus important that the clinician perform a complete review of systems and directly question the patient regarding the presence of specific symptoms, such as rashes or skin changes, photosensitivity, Raynaud’s phenomenon, mouth ulcers, and dryness in the eyes and mouth.

## Functional Losses

Questioning regarding functional loss is essential for understanding the impact of a musculoskeletal disorder and, in turn, developing a plan of management. The questioning should span the spectrum of activities, from simple activities of daily living such as dressing and grooming to more physically demanding activities such as sports. In some cases, the functional loss may be quite severe, impairing basic activities such as stair climbing and gripping, while in others it may be quite subtle, detectable only as a reduction in strenuous activities such as jogging.

## Family History

A number of rheumatic diseases have a strong genetic basis. Disorders such as ankylosing spondylitis are much more common in HLA-B27–positive families than in the general population. Questioning regarding family history should not be restricted only to ascertaining whether other family members have a similar arthritis, but should be as complete as possible regarding autoimmune diseases, many of which (e.g., RA, thyroid disease, and diabetes) tend to cluster in families.

## PRINCIPLES OF RHEUMATOLOGICAL EXAMINATION

Evaluation of musculoskeletal complaints involves examination of the joints and their soft tissue support structures, the bony skeleton, and the muscle groups that move the skeletal structures (3). The joints, bones, and muscles can be directly accessible to examination, as in the extremities, or they may be inaccessible to direct examination, as in the case of the spine and hip joints.

All joint areas should be inspected from multiple angles to assess for deformity (sometimes seen as loss

of symmetry with the contralateral side), muscular atrophy, swelling, erythema, or surgical scars. Extremity joints should be palpated for warmth using the dorsum of the hand. Superficial joints are normally slightly cooler than the surrounding soft tissue. The joint line and major bony and soft tissue structures should be palpated for tenderness.

Functional joint motion should be tested both by having the patient actively move the joint to its extremes and by having the examiner passively move the joint through its range. Tenderness elicited by gentle stress on the joint at its end range of motion (stress tenderness) is characteristic of joint pathology and may be absent in pain syndromes such as fibromyalgia. Loss of range of motion is seen both with acute articular inflammation and with chronic arthritis and damage. Joints should be assessed for the presence of swelling. The cardinal signs of articular inflammation are warmth, joint line tenderness, pain on motion (particularly at the extremes of the range of motion), and intra-articular swelling or effusion.

Deformity caused by loss of alignment is a consequence of destructive arthropathies such as RA. The damage is commonly associated with loosening of the soft tissue support structures surrounding the joints. In some cases, the joint may not exhibit any obvious deformity, but may be unstable when put through its range of motion or is mechanically stressed.

A key part of the musculoskeletal evaluation involves examination of the ligaments, tendons, menisci, and muscles. These structures may be the primary source of the pathology, or may be involved secondary to the articular pathology. Examination of individual muscle groups requires a basic knowledge of the origin, insertion, and primary action of each muscle. Atrophy and weakness of the muscles surrounding a particular joint is an important indicator of chronic articular pathology.

## A Screening Musculoskeletal Exam

The GALS (Gait, Arms, Leg, Spine) system has been devised to screen rapidly for musculoskeletal disease (4). Initially, the patient is asked three basic questions: “Have you any pain or stiffness in your muscles, joints, or back?”; “Can you dress yourself completely without any difficulty?”; “Can you walk up and down stairs without any difficulty?”. Depending on the answers to the questions, further questioning is undertaken to explore specific areas.

The examiner then systematically inspects the patient’s gait, arms, legs, and spine, first with the patient standing still and then responding to instructions (Table 2A-1). Abnormalities detected on this screening are followed up with a more detailed regional or generalized musculoskeletal examination.

**TABLE 2A-1. MAIN FEATURES OF THE GAIT, ARMS, LEG, SPINE (GALS) SCREENING INSPECTION.**

POSITION/ACTIVITY	NORMAL FINDINGS
Gait	Symmetry, smoothness of movement; normal stride length; normal heel strike, stance, toe-off, swing through; able to turn quickly
Inspection from behind	Straight spine, normal symmetric paraspinal muscles, normal shoulder and gluteal muscle bulk, level iliac crests, no popliteal cysts, no popliteal swelling, no hindfoot swelling/deformity
Inspection from the side	Normal cervical and lumbar lordosis, normal thoracic kyphosis
“Touch your toes.”	Normal lumbar spine (and hip) flexion
Inspection from the front	
Arms	
“Place your hands behind your head, elbows out.”	Normal glenohumeral, sternoclavicular, and acromioclavicular joint movement
“Place your hands by your side, elbows straight.”	Full elbow extension
“Place your hands in front, palms down.”	No wrist/finger swelling or deformity, able to fully extend fingers
“Turn your hands over.”	Normal supination/pronation, normal palms
“Make a fist.”	Normal grip power
“Place the tip of each finger on the tip of the thumb.”	Normal fine precision, pinch
Legs	Normal quadriceps bulk/symmetry, no knee swelling or deformity, no forefoot/midfoot deformity, normal arches, no abnormal callous formation
Spine	
“Place your ear on your shoulder.”	Normal cervical lateral flexion

SOURCE: Modified from Doherty et al., *Ann Rheum Dis* 1992;51:1165–1169, with permission of *Annals of Rheumatic Diseases*.

## EXAMINATION OF SPECIFIC JOINT AREAS

### The Hand and Wrist

A number of generalized arthropathies have distinctive patterns of hand involvement, and the recognition of these patterns is highly valuable diagnostically. Examination of the hands should be initiated with the patient sitting comfortably with the hands open and the palms facing down. In this position, the examiner can inspect the alignment of the digits relative to the wrist and forearm. Atrophy of the intrinsic muscles of the hands can readily be appreciated as a hollowing out of the spaces between the metacarpals. The nails should be inspected for evidence of onycholysis or pitting suggestive of psoriasis. Redness and telangiectasia of the nail fold capillaries can be detected on close inspection, and is often indicative of a connective tissue disease such as systemic lupus erythematosus (SLE), scleroderma, or dermatomyositis. Tightening of the skin around the digits, or sclerodactyly, is typical of scleroderma and is usually both visible and palpable. The pulp of the digits should be examined for the presence of digital ulcers, also seen most commonly in scleroderma.

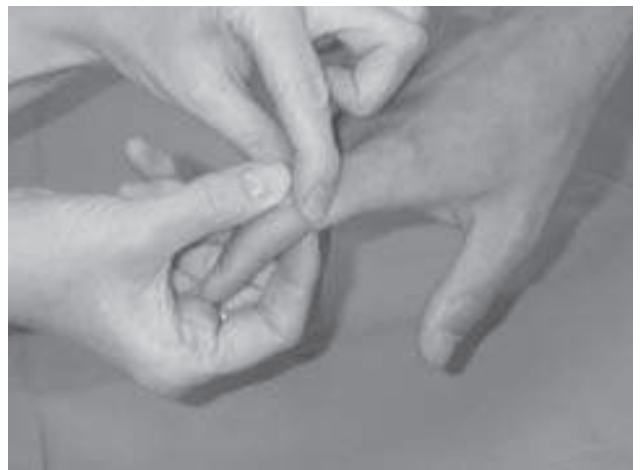Articular swelling of the distal interphalangeal (DIP) and proximal interphalangeal (PIP) joints can represent bony osteophytes as in the case of Heberden's and Bouchard's nodes in the DIP and PIP joints, respectively, or can represent an intra-articular effusion associated with synovitis in the joint. Palpation will help in differentiating these. Swelling and redness of an entire digit, termed *dactylitis*, is highly suggestive of a spondylarthropathy such as psoriatic arthritis or reactive arthritis.

Swelling of the metacarpophalangeal (MCP) joints can be visually appreciated as a fullness in the valleys normally found between the knuckles (heads of the metacarpal bones). In cases of RA where the MCP synovitis has been longstanding, it is often associated with ulnar subluxation of the extensor tendons, resulting in the ulnar drift of the digits that is typical of this diagnosis. Swelling on the dorsum of the wrist area can result from synovitis of the wrist or tenosynovitis of the extensor tendons. Getting the patients to gently wiggle the fingers helps differentiate these two findings in that the swelling will tend to move with the tendons if it is a result of tenosynovitis. Inspection of the palmar aspect of the hands is important for identifying atrophy of the thenar or hypothenar eminences, which can result either from disuse due to articular involvement of the wrist or, in the case of the thenar eminence, carpal tunnel syndrome.

Global function of the hand should be evaluated by asking the patient to make a full fist and to fully extend

and spread out the digits. Pincer function of the thumb and fingers should be tested. The grip strength can be estimated by having the patient squeeze two of the examiner's fingers. Individual hand joints should be palpated to determine the presence of joint line tenderness and effusion, these being the most important indicators of synovitis. The technique for palpating the DIP and PIP joints is similar. The thumb and index finger of one hand palpates in the vertical plane, while the thumb and index finger of the other hand palpates in the horizontal plane (Figure 2A-1). Alternating gentle pressure between the two planes will displace small amounts of synovial fluid back and forth, allowing the examiner to detect effusions in these small joints. Likewise, tenderness suggestive of synovitis can be elicited by this technique. The technique for palpating the MCP joints is somewhat modified because of the inability to directly palpate these joints from the horizontal plane. The thumbs are used to palpate the dorsolateral aspects of the joint, while the index fingers palpate the palmar aspect.

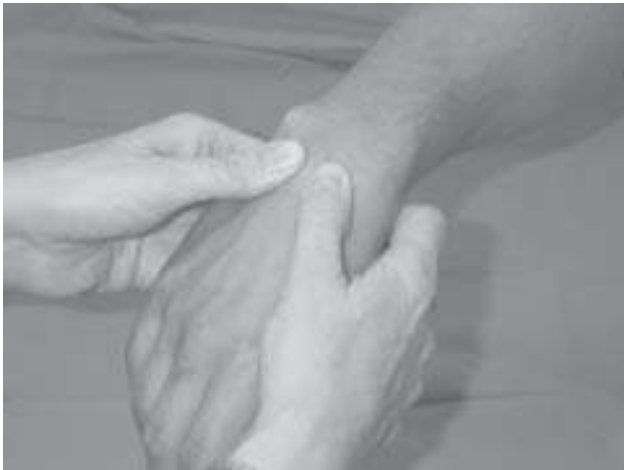Palpation of the wrist involves a similar technique to that used for the MCPs. The thumbs are used to palpate the dorsum of the joint, while the index fingers palpate the volar aspect (Figure 2A-2). Synovial thickening and tenderness suggestive of wrist joint synovitis can usually be palpated on the dorsum of the joint. Particular attention should be paid to swelling and tenderness in the area just distal to the ulnar styloid, where the extensor and flexor carpi ulnaris tendons are directly palpable. This area is very commonly involved in early RA. Pain and tenderness confined to the radial aspect of the wrist are most commonly due to either OA of the first carpo-



**FIGURE 2A-1**

Technique for examining the small joints of the hands and feet. The thumb and index finger of the examiner's hands are used to gently ballot small amounts of intra-articular fluid back and forth to elicit evidence of joint line tenderness.



**FIGURE 2A-2**

The dorsum of the wrist joint is palpated for tenderness and swelling using the examiner's thumbs. The wrist should be examined in slight flexion to allow the joint line of the radiocarpal, intercarpal, and carpometacarpal joints to be optimally palpated.

metacarpal joint, or to DeQuervain's tenosynovitis. All the joints of the hand and wrist should be evaluated for stress tenderness.

## The Elbow

Flexion and extension of the forearm occur exclusively at the elbow joint and involve the hinge type of articulation between the proximal ulna and distal humerus. In examining the elbow, a number of surface landmarks need to be identified. These are the olecranon process, the medial and lateral epicondyles of the humerus, and the radial head. A triangular recess is formed in the lateral aspect of the joint between the olecranon process, the lateral epicondyle, and the radial head. This recess is the point where the synovial cavity of the elbow is most accessible to inspection and palpation.

Examination of the elbow should be undertaken with the patient sitting comfortably and the entire arm being well supported in order to eliminate muscle tension. Initially the joint should be inspected with forearm flexed to 90°. Particular attention should be paid to the lateral recess described above. Obvious bulging in this area is highly suggestive of an effusion and synovitis. In contrast, swelling directly over the olecranon process is more suggestive of olecranon bursitis. Any process that causes true synovitis of the elbow is typically associated with a reduction in the range of motion of the joint, both in flexion–extension and in supination–pronation. Having the patient extend the forearm as much as possible will detect the presence of a flexion contracture, this being an almost invariant feature of elbow synovi-

tis. With this maneuver, the bulge in the lateral recess will tend to enlarge, becoming more tense due the reduction in the internal dimension of the elbow in the position of extension.

The synovial cavity and joint line can best be palpated for swelling and tenderness in the area of the lateral recess. This is also the site where arthrocentesis of the elbow is performed. It should be noted that pain in the lateral aspect of the elbow area is a common clinical problem, and is usually due to lateral epicondylitis or tennis elbow rather than elbow joint pathology. Tenderness directly palpable over the lateral epicondyle and with stressing the wrist and finger extensors is suggestive of this diagnosis.

## The Shoulder

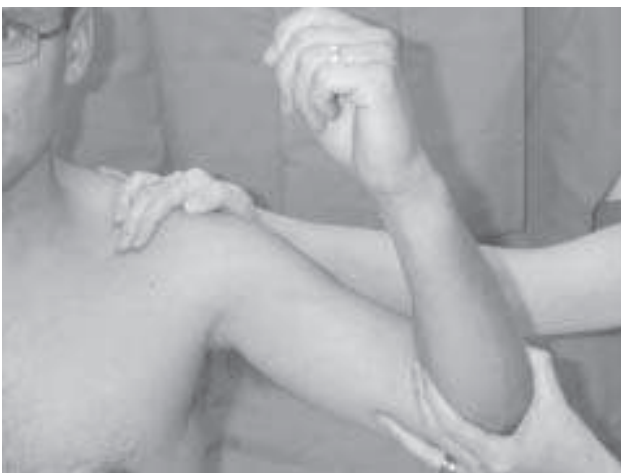Proper examination of the shoulder should always begin with appropriate visualization of the entire shoulder girdle area, both from the front and the back. This includes the sternoclavicular, glenohumeral, and acromioclavicular joints as well as the scapulothoracic articulation. Comparison should be made with the contralateral shoulder. Any asymmetry between the two sides should be noted. For example, patients with rotator cuff tears often hold the affected shoulder higher than the other side. Atrophy of the shoulder girdle musculature is an important sign of chronic glenohumeral joint pathology, as occurs in RA. This is most evident as squaring of the shoulder due to deltoid atrophy and scooping out of the upper scapular area due to supraspinatus atrophy. Effusions in the shoulder joint are visible anteriorly just medial to the area of the bicipital groove, and if large enough are also evident laterally below the acromion. It should be noted that large amounts of fluid can accumulate in the glenohumeral joint space without much visible evidence due to considerable redundancy in the joint capsule.

After inspecting the shoulder area in the resting position, the patient is asked to demonstrate the active range of motion of the shoulder. Abduction is observed as the patient moves both outstretched arms from their side in the lateral plane until the palms meet overhead. The movement is evaluated for discomfort, symmetry, and fluid scapulohumeral coordination. Patients with shoulder pathology will usually move the arm forward somewhat in order to complete the maneuver. External rotation can then be tested by having the patient attempt to touch the back of their head with the palm of the hand from the fully abducted position. If abduction is abnormal, active flexion should be tested by having the patient lift the outstretched arm from their side directly up in front of them. Active internal rotation and extension is observed by having the patient reach behind their back and attempt to have their fingertips touch the highest point possible on their scapula.

Palpation should include the entire shoulder girdle area. The sternoclavicular joint is palpated, then the fingers are walked laterally over the clavicle to the acromioclavicular joint, which is palpated for tenderness and swelling. The subacromial space, containing the supraspinatus tendon and subacromial bursa, lies directly below the acromion. Immediately below the acromioclavicular joint, the coracoid process should be identified. The short head of the biceps inserts on this process. The long head of the biceps can be palpated lateral to this in the bicipital groove. The anterior aspect of the glenohumeral joint can be palpated between the coracoid process and the long head of the biceps and follows the contour on the rounded anterior aspect of the humeral head. Shoulder synovitis can be palpated in this area as joint line tenderness and/or boggy effusion.

Passive range of shoulder motion is then evaluated. The most informative parts of the range of motion are internal/external rotation and abduction. When testing these movements it is very important to immobilize the scapula to prevent rotation at the scapulothoracic area. In this way, glenohumeral motion can be isolated and appropriately evaluated. One effective technique to achieve this is to firmly press down on the top of the shoulder area with the palm of one hand, while the other hand moves the arm through the range of motion (Figure 2A-3). Internal/external rotation should be tested with the arm by the patient's side and with the arm abducted to 90°. Examination of the patient in the supine position may aid in relaxing musculature in patients who are unable to fully relax during this maneuver.

A large number of special maneuvers have been described that suggest specific clinical syndromes in the



**FIGURE 2A-3**

Glenohumeral joint motion is best examined with the elbow flexed to 90° and the upper arm in partial abduction. Internal and external rotation of the shoulder are then examined in this position. Care should be taken to immobilize the scapula using a technique such as that shown.

shoulder. The predictive value of these maneuvers is modest (5). Forced supination of the hand with the elbow flexed at 90° will cause pain in the area of the long head of the biceps in patients with bicipital tendinitis. Impingement of the subacromial bursa or supraspinatus tendon is suggested by pain with forced internal rotation and flexion of the glenohumeral joint from a position of 90° flexion with the elbow flexed at 90°. Supraspinatus tendinitis can be detected by having the patient position their outstretched arm at 90° of abduction while maximally internally rotating the glenohumeral joint such that the thumb is pointing downward. The examiner then asks the patient to resist attempts to push the arm down. In patients with supraspinatus tendinitis, the maneuver will be associated with pain, and may result in the patient suddenly dropping the arm.

## The Hip

Pain resulting from hip arthritis is typically experienced in the groin or, less commonly, the buttock. It tends to radiate down the anteromedial aspect of the thigh, occasionally down to the knee. Pain in the lateral trochanteric area is most often indicative of bursitis involving the trochanteric bursa.

Because the hip joint cannot be directly examined, the examiner needs to glean important diagnostic clues from observing the patient's gait, buttock and thigh musculature, and from evaluating passive range of motion of the hip joint. As with all load bearing joints, evaluation of functional joint motion needs to be assessed under load with the patient walking and standing. Subtle hip pathology may be detected by having the patient perform a squat. The patient with true hip disease often walks with a coxalgic gait, tending to quickly swing the pelvis forward on the affected side in order to avoid weight bearing on the hip affected by arthritis. If the hip arthritis is prolonged and severe, the buttock musculature tends to atrophy, as does the thigh musculature. In severe cases, the abductor muscles are unable to hold the pelvis in a horizontal position when the patient is asked to stand only on the affected hip. This forms the basis of the Trendelenburg test, where the patient's pelvis tends to sag down on the contralateral side when the patient is asked to hold their entire weight on the affected leg.

With the patient in the supine position, passive range of motion should initially be screened by log rolling the entire extended leg. The leg is then flexed maximally to assess completeness of this motion. With the knee flexed to 90° and the hip flexed to 90°, internal and external rotation of the hip are then tested. Care should be taken that the hip movements are isolated, and that the patient's pelvis is not rotating to compensate for lost range of motion. Pain and loss of motion on internal rotation are particularly sensitive indicators of hip

pathology. Flexion contracture of the hip tends to accompany longstanding severe hip arthritis.

## The Sacroiliac Joint

Palpation of the sacroiliac (SI) joint is undertaken with the patient lying flat on their abdomen. With the palm of the examiner's hand held around the iliac crest, the thumb tends to fall directly over the joint which extends down below the dimples in the posterior pelvic area. To elicit tenderness in the SI joint, direct pressure is applied with the thumb in this area. In addition to direct palpation, the examiner can perform other maneuvers to further establish the presence of sacroiliitis. Direct pressure over the sacrum will produce pain in an inflamed SI joint. Gaenslen's maneuver is performed by having the patient hyperextend their leg over the edge of the examining table, thereby stressing the ipsilateral SI joint.

## The Spine

The spine should be examined initially with the patient standing and the entire spine well visualized. The normal curvature of the spine, lumbar lordosis, thoracic kyphosis, and cervical lordosis should be evaluated by observing the patient from the both the back and the side, and any loss or accentuation of these curves noted. If scoliosis is noted with the patient standing upright, they should be asked to bend forward and flex the spine to evaluate the effects of this movement on the scoliosis. True scoliosis will be present irrespective of the state of spinal flexion, while a functional scoliosis due to leg length discrepancy will tend to decrease with spinal flexion. The level of the iliac crests relative to the spine should also be evaluated by observing the patient from the back, and the examiner sitting with their eyes at approximately the level of the iliac crests. A tilted pelvis can be due to compensation for a primary scoliosis in the spine or, alternatively, due to a leg length discrepancy.

The range of motion of the entire spine should be examined in segments. The lumbar spine is assessed by having the patient attempt to touch their toes and then extend their back. Lateral flexion is assessed by having the patient reach their fingertips as far as possible down the lateral aspect of their leg. Lateral rotation, which involves both the lumbar and thoracic spine, is tested by having the patient turn their upper body with the examiner holding the pelvis stable.

The Schober test is performed to specifically assess movement in the lumbar spine. With the patient standing, a distance of 10 cm is measured up the lumbar spine from the lumbosacral junction at the level of the sacral dimples. Marks are placed at both ends of this 10 cm segment. The patient is then asked to flex forward as far as possible, attempting to touch their toes. With this

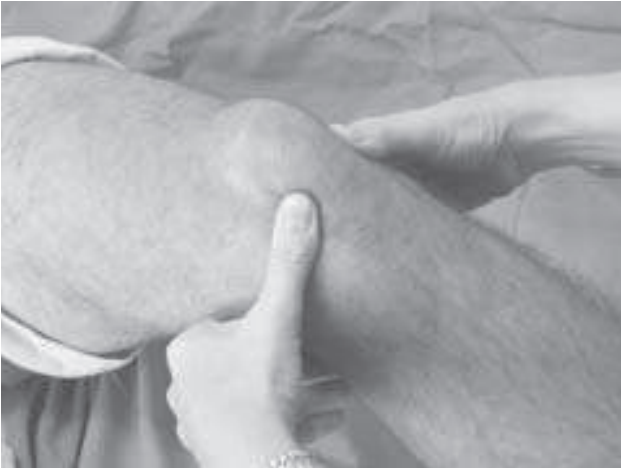motion, the marks identifying this 10 cm segment normally expand to 15 cm or more, indicative of distraction between the vertebrae. While reduction in this measurement is not specific for any particular pathology, it can be used over time to follow disorders with progressive loss of motion, such as ankylosing spondylitis.

Patients presenting with symptoms suggestive of a lumbar radiculopathy, such as pain and parasthesia shooting down the leg, need to undergo an examination of the lumbosacral area and a detailed neurological examination of the leg. Maneuvers that put traction on the lumbar spinal roots are used to provide further evidence of a radiculopathy. The most commonly used of these maneuvers is the straight leg raising test, where the patient lies in the supine position and the leg is passively raised by the examiner with the knee fully extended. A positive test requires that the patient experience pain and parasthesia shooting down the leg to the level of the foot.

Cervical range of motion begins with the patient upright and the examiner in front. The patient is asked to flex, extend, laterally flex (patient attempts to touch their ear to their shoulder), and laterally rotate (patient attempts to touch their chin to their shoulder) their head. Movements should be evaluated for symmetry, fullness of motion, and discomfort. Gentle passive range of motion may be attempted with the patient supine. Spinous processes and surrounding musculature should be palpated for spasm or tenderness. It should be noted that pain in the neck area often radiates down the arm, up the occiput, or down to the scapular area. The pain may be aggravated by particular parts of the range of motion.

## The Knee

Examination of the knee starts with inspection of the patient's gait and with the patient standing. When inspecting from the front, attention should first be paid to the areas above and below the knee. Atrophy of the quadriceps usually indicates chronic knee pathology. Swelling due to synovial fluid accumulation or synovial infiltration and thickening is most readily appreciated in the suprapatellar bursa. When a large effusion is present, it can be seen to also cause bulging of both the lateral and medial compartments of the knee. Inspection of the knee from the back with the patient standing up is the best way to evaluate the alignment of the femur relative to the tibia. Varus deformities of the knee causing a bow-legged appearance most commonly result from OA preferentially involving the medial compartment. Valgus deformities, causing a knock-knee appearance are more commonly associated with RA. Posterior inspection is also important for detecting popliteal or Baker's cysts, which can be large enough to track down the calf.

**FIGURE 2A-4**

The joint line of the knee is palpated on the medial and lateral aspects for tenderness suggestive of synovitis. Stability of the cruciate ligaments can also be assessed in this position. Using the bulge sign or patellar tap sign, an effusion can be detected in the knee with the joint fully extended (see text for details).

After inspecting the patient in the standing position, the knee is evaluated with the patient in the supine position, and the joint fully extended. Flexion contractions should be noted. Loss of normal contours may suggest swelling. The knee should be palpated for warmth. Bony and soft tissue landmarks should be palpated for tenderness, including the anserine bursa—a common nonarticular source of knee pain. The medial and lateral joint line are palpated for tenderness with the knee in partial flexion (Figure 2A-4).

Detection of synovial fluid in the knee is an important diagnostic clue. Large amounts of fluid cause distention of the joint in the suprapatellar area, as well as the medial and lateral compartment. The fluid can be confirmed by firmly pushing the swelling in the suprapatellar area down into the main compartment of the knee with the palm of one hand. While maintaining pressure over the suprapatellar area, the examiner's other hand is used to either ballot the fluid back and forth between the medial and lateral compartments of the knee, or alternatively to perform the patellar tap by pushing the patella up and down against the femoral condyles. Small amounts of fluid in the knee may be detected using the bulge sign. The medial aspect of the knee is stroked from the inferior aspect towards the suprapatellar area in order to move the fluid into the lateral compartment. The lateral aspect of the knee is then stroked in a similar manner while the medial compartment is observed for the return of the fluid bulge.

While firmly supporting the joint with one hand (or by holding the foot in the examiner's armpit area), varus and valgus stress are gently applied to the joint to test

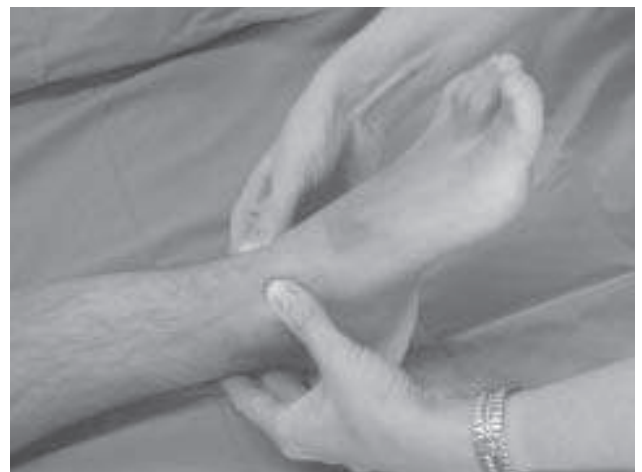the medial and collateral ligaments. The cruciate ligaments are tested using the drawer sign, where antero-posterior stress is placed on the upper tibia with the knee in flexion. Instability of the ligaments will result in the tibia moving back and forth relative to the femur, much as a drawer would if pushed back and forth.

## The Ankle and Hindfoot

The ankle and hindfoot should be examined as a unit, because arthropathies often involve several structures in this area. Valgus deformities of the ankle and hindfoot can best be seen by inspecting the area from behind with the patient standing. Swelling in the ankle area eliminates the normal contours associated with the malleoli.

The joint line of the ankle is palpated anteriorly (Figure 2A-5). Boggy swelling and tenderness in this area are typical of ankle synovitis. Tenderness and swelling posteriorly at the insertion of the Achilles tendon usually indicates enthesitis, although this can also result from bursitis of the retrocalcaneal bursa. Tenderness in the heel region can indicate plantar fasciitis, another enthesitis associated with spondylarthropathies but also common in overuse injuries and arch abnormalities.

The ankle and hindfoot unit should be put through the range of motion, isolating parts of the range associated with specific joints. The ankle proper, or talotibial joint, is only capable of dorsi and plantar flexion. Pain and limitation in this part of the range is associated with ankle synovitis. The subtalar joint, separating the talus and the calcaneus, can be tested by rocking the calcaneus laterally from side to side with one hand, while

**FIGURE 2A-5**

Palpation for tenderness and swelling in the ankle is undertaken medial and lateral to the extensor tendons on the anterior part of the joint below the malleoli.



holding the talus stable with the other. Talonavicular motion is tested by stabilizing the talus and calcaneus and rotating the midfoot.

## The Midfoot and Forefoot

Observation of the patient in the standing position will reveal abnormalities in the longitudinal arch and the anterior part of the foot. Pes planus (flat foot, collapsed arch) or pes cavus (high arch) will be most evident with the patient standing. Hallux valgus deformities causing bunions are some of the most commonly observed problems in the joints.

Swelling of the metatarsophalangeal joints (MTPJ) causes a visible spreading of the toes referred to as the daylight sign. Direct pressure over each of the metatarsophalangeal joints will confirm the presence of tenderness and swelling. In cases of advanced RA, subluxation of the MTPJ results in a hammer toe deformity, which can cause skin breakdown on the dorsum of the toes from constant rubbing against the footwear. Inflammation of the interphalangeal joints of the toes is more common with spondylarthropathies. In some cases the

entire digit becomes swollen and inflamed, a process termed *dactylitis* and referred to as a sausage digit. Examining the plantar aspect of the forefoot is important for identifying areas of callus formation. These tend to occur in conjunction with subluxation of the MTPJ, where the metatarsal head can be directly palpated subcutaneously.

## REFERENCES

1. Dieppe P, Sergent J. History. In: Klippel J, Dieppe P, eds. Rheumatology. Mosby, London 1998:1.1–1.6.
2. Hubscher O. Pattern recognition in arthritis. In: Klippel J, Dieppe P, eds. Rheumatology. Mosby, London 1998:3.1–3.6.
3. Grahame R. Examination of the patients. In: Klippel J, Dieppe P, eds. Rheumatology. Mosby, London 1998:2.1–2.16.
4. Doherty M, Dacre J, Dieppe P, Snaith M. The GALS locomotor screen. *Ann Rheum Dis* 1992;51:1165–1169.
5. Calis M, Acgun K, Birtane M, Karacan I, Calis H, Fikret T. Diagnostic values of clinical diagnostic tests in subacromial impingement syndrome. *Ann Rheum Dis* 2000;59:44–47.

# Evaluation of the Patient

## B. Laboratory Assessment

KERSTIN MOREHEAD, MD

- Laboratory testing is often valuable for screening for disease, confirming diagnoses, establishing disease stage, determining prognosis, gauging disease activity, and following responses to therapy.
- The erythrocyte sedimentation rate (ESR) and C-reactive protein (CRP) frequently correlate well with disease activity in inflammatory disorders.
- Rheumatoid factor (RF) and anti-cyclic citrullinated peptide (anti-CCP) anti-bodies are helpful in diagnosing rheumatoid arthritis. The specificity of RF for rheumatoid arthritis is poor.
- Antinuclear antibodies (ANA) are found in many patients with rheumatic diseases and in essentially all patients with systemic lupus erythematosus (SLE) and systemic sclerosis. Under the proper clinical conditions, the finding of a positive ANA assay is an indication for additional investigations directed at identifying the precise autoantibody leading to the ANA pattern.
- Among others, anti-Ro, -La, -Sm, and -RNP antibodies may all result in a positive ANA. These autoantibodies are associated with a range of different rheumatic diseases.
- Positive immunofluorescence assays for antineutrophil cytoplasmic antibodies (ANCA) should be confirmed by enzyme immunoassays for antibodies directed specifically against two antigens: proteinase-3 and myeloperoxidase.
- Decreased serum complement levels usually indicate a disease process mediated by immune complex deposition within tissues.

Laboratory testing is an important part of the evaluation for many patients with possible rheumatic diseases. As the understanding of rheumatic disease progresses, new biomarkers are developed and the utility of existing ones is refined. Laboratory tests can be valuable guides for screening, confirming diagnosis, establishing disease stage, and prognosis, as well as for following disease activity and response to treatment. Because no single test can provide absolute certainty about diagnosis, prognosis, or state of disease activity, however, results must be interpreted in the context of the broader clinical picture. Sensitivity, specificity, positive and negative predictive values, and likelihood ratios all warrant careful consideration when interpreting the utility of any test. Although laboratory testing has grown substantially as an aid to clinical diagnosis and management over the past several decades, treatment decisions are rarely based on the result of a single test alone. In addition to appreciating the strengths and shortcomings of testing approaches, the clinician must also be aware of the variability that often exists between different assay methods and individual laboratories. In general, the most useful tests are those that are ordered to answer well-defined questions.

### ERYTHROCYTE SEDIMENTATION RATE

Inflammatory stress alters hepatic synthesis of plasma proteins. As a result, fibrinogen and immunoglobulin levels increase during the acute phase response. When red blood cells (RBCs) interact with these proteins, they form clusters that sediment at a faster rate than individual RBCs. In chronic states of inflammation, decreased serum albumin and hematocrit levels also lead to increased rates of erythrocyte sedimentation.

#### Method (Westergren)

Whole serum is anticoagulated with sodium citrate and allowed to stand. After 1 hour, the distance in millimeters between the top of the tube and the erythrocyte sediment is measured. The test is sensitive to handling and temperature (1). Normal values are not adjusted for age or gender in most laboratories, yet these characteristics have well-known (if erratic) influences on the erythrocyte sedimentation rate (ESR). The ESR generally increases with age and is somewhat higher in women.

The upper limits of normal for a man is equal to the age divided by 2; for a woman, add 10 to the age and divide by 2 (2).

## Interpretation

The ESR is sensitive for most types of inflammation, but cannot distinguish if the underlying cause is infectious, inflammatory, or paraneoplastic (3). A normal value may help to rule out inflammatory disease, but an increased ESR, especially if the increase is only moderate, can be confusing. In addition, the normalization of a high ESR often lags behind the resolution of inflammation, making it less than ideal for monitoring disease activity. Along with normal elevation due to age and gender, the ESR can be increased by any condition that raises serum fibrinogen, such as diabetes, end-stage renal disease, and pregnancy. Conversely, the ESR can be lowered by congestive heart failure, sickled erythrocytes, and the presence of cryoglobulins.

## C-REACTIVE PROTEIN

The c-reactive protein (CRP) is an acute phase protein synthesized in response to tissue injury. Serum CRP levels change more quickly than the ESR; with sufficient stimulus, the CRP can increase within 4 to 6 hours and normalize within a week (4). The CRP is often measured simultaneously with (and sometimes in place of) the ESR as a general measure of inflammation. Although CRP and ESR values tend to correspond with each other, some patients' disease processes appear to correlate better with one measure or the other.

## Method

Specific antibodies to CRP allow direct quantification by a variety of means. Nephelometry uses antibodies to bind target proteins and then measures the scatter of light by antigen-antibody complexes. The enzyme-linked immunosorbent assay (ELISA) uses coated plates to form antigen-antibody complexes. These complexes are detected by addition of secondary antibodies labeled with an enzyme that, when mixed with a substrate, produces color that is measured by spectrophotometry. Because the CRP is a stable serum protein and its measurement is not affected by other serum components, it tends to be less variable than the ESR. The CRP is affected by age and gender, as is the ESR (5). In general, levels  $<0.2$  mg/dL are considered normal and levels  $>1$  mg/dL are deemed consistent with inflammation, but there is considerable laboratory-to-laboratory variation.

## Interpretation

Because a certain degree of injury is required before CRP is synthesized, a normal or indeterminate value

does not exclude an inflammatory process. Moreover, other disease processes, including heart disease, infection, and malignancy, can lead to CRP elevations, as can obesity, diabetes, and cigarette smoking.

## RHEUMATOID FACTOR

Rheumatoid factor (RF) is an autoantibody that binds to the Fc region of human IgG. IgM is the most common RF isotype, but IgG and IgA RF may also be detected in the serum (6).

## Method

The latex fixation test measures only RF IgM by precipitating the antibody with IgG-coated latex particles mixed with serial dilutions of serum. Titers greater than 1:20 are positive. Nephelometry and ELISA are able to detect all three isotypes.

## Interpretation

In established rheumatoid arthritis (RA), RF has a sensitivity on the order of 70%. In early RA the sensitivity is somewhat lower, approximately 50%, as some patients seroconvert only after having clinical disease for weeks or months. A positive RF assay, far from specific for RA, can be found in many other autoimmune diseases, mixed essential cryoglobulinemia (see cryoglobulinemia, below), chronic infections, sarcoidosis, malignancy, and a small percentage of healthy people. The IgA isotype has been linked to erosive disease and to rheumatoid vasculitis, but its precise clinical utility remains unclear. Higher titers of RF are associated with more severe disease, but as a longitudinal measure of disease activity RF fares poorly. CRP values may be more reliable for monitoring disease activity (7).

## ANTI-CYCLIC CITRULLINATED PEPTIDE ANTIBODIES

Anti-cyclic citrullinated peptide antibodies (ANTI-CCP) are autoantibodies directed against the amino acids formed by the posttranslational modification of arginine. Some investigators believe anti-CCP antibodies have a role in the pathogenesis of RA (8).

## Method

IgG anti-CCP are measured by ELISA using synthetic citrullinated peptides. Reference ranges vary (9).

## Interpretation

Anti-cyclic citrullinated peptide antibodies have a sensitivity for RA that is similar to that of RF, but anti-CCP antibodies are much more specific. These test characteristics lend considerable usefulness to anti-CCP antibodies in the setting of seronegative patients suspected of having RA, patients with other forms of connective tissue disease who are RF positive, and patients with hepatitis C or other infections that are often associated with RF positivity. Anti-CCP antibodies are often detectable in early RA and, in some cases, antedate the onset of inflammatory synovitis. Although anti-CCP antibodies may be a better predictor of erosive disease than is RF, they do not correlate with extra-articular disease. A positive anti-CCP combined with a positive RF IgM correlates strongly with radiographic progression. Anti-CCP levels are not useful in the longitudinal monitoring of disease activity (10).

## ANTINUCLEAR ANTIBODIES

Antinuclear antibodies (ANA) are a diverse group of autoantibodies that react with antigens in the cell nucleus. Different patterns reflect different nuclear components including nucleic acid, histones, and centromeres (Table 2B-1).

### Method

Hep-2 cells (a human tumor cell line) are incubated with serial dilutions of serum. Using immunofluorescence microscopy, labeled antihuman IgG is used as a stain. The result reflects the highest serum dilution

that is positive for staining and the pattern of the stain.

## Interpretation

Aninuclear antibody assays are nearly universally positive in SLE, to the extent that ANA-negative lupus is virtually nonexistent. Patients with systemic sclerosis (scleroderma) and many other connective tissue diseases are also ANA positive with a very high frequency, often in high titers. Depending on the exact technique used, up to 30% of healthy people may have a positive titer (11). The prevalence of positive ANAs increases in women and older people. A positive ANA is not specific for SLE or autoimmune disease, especially if it is transient or in low titer.

## Specific Autoantibodies

Autoantibodies directed against individual antigens have increased specificity for particular diseases. Some of these autoantibodies also predict disease severity (Table 2B-2) (12). These are ordered separately from the ANA test.

## ANTINEUTROPHIL CYTOPLASMIC ANTIBODY

Antineutrophil cytoplasmic antibodies (ANCA) are autoantibodies that react with the cytoplasmic granules of neutrophils. Two general staining patterns, cytoplasmic (C-ANCA) or perinuclear (P-ANCA) can be detected by immunofluorescence. In forms of systemic

**TABLE 2B-1.** ANTINUCLEAR ANTIBODY PATTERNS.

PATTERN	NUCLEAR ANTIGEN	CLINICAL ASSOCIATIONS
Homogenous	Double-stranded DNA	Systemic lupus erythematosus
Diffuse	Histone	Drug reaction Systemic lupus erythematosus
	Topoisomerase I	Systemic sclerosis
Speckled	Extractable nuclear antigens (Sm, RNP)	Mixed connective tissue disease Systemic lupus erythematosus
	Ro-SSA/La-SSB	Sjögren's syndrome
	Other	Poly/dermatomyositis Various autoimmune diseases Infection Neoplasia
Nucleolar	RNA-associated antigens	Systemic sclerosis
Peripheral	Double-stranded DNA	Systemic lupus erythematosus
Centromere	Centromere	Limited systemic sclerosis



**TABLE 2B-2.** AUTOANTIBODIES IN RHEUMATIC DISEASES.

TYPE	DESCRIPTION	CLINICAL ASSOCIATION
Anti-dsDNA	Antibodies to double-stranded DNA	High specificity for SLE Often correlates with more active, more severe disease ELISA test is very sensitive and can be positive in other diseases, normal people
Anti-histone	Five major types exist	SLE, drug-induced SLE, other autoimmune disease SLE patients will likely be positive for other autoantibodies as well
Anti-ENA	Sm (Smith) RNP (ribonucleoprotein) RNA-protein complexes	High specificity for SLE Mixed connective tissue disease Higher prevalence in African American and Asian patients
Anti-SSA (Ro)	Ribonucleoproteins	SLE (especially subacute cutaneous lupus), neonatal lupus, Sjögren's syndrome
Anti-SSB (La)	Ribonucleoproteins	Sjögren's syndrome, SLE, neonatal SLE
Anti-centromere	Antibody to centromere/kinetochore region of chromosome	Limited scleroderma High rate of pulmonary hypertension Primary biliary sclerosis
Anti-Scl 70	Antibodies to DNA topoisomerase 1	Diffuse scleroderma Risk of pulmonary fibrosis
Anti-Jo-1	Antibody to histidyl tRNA synthetase	Poly/dermatomyositis Patients tend to have interstitial lung disease, Raynaud's phenomenon, mechanic's hands, arthritis Typically resistant to treatment
Anti-SRP	Antibody to signal recognition protein	Cardiomyopathy Poor prognosis
Anti-PM-Scl	Antibody to nucleolar granular component	Polymyositis/scleroderma overlap syndrome
Anti-Mi-2	Antibodies to a nucleolar antigen of unknown function	Dermatomyositis Favorable prognosis

vasculitis, such as Wegener's granulomatosis, microscopic polyangiitis, and the Churg–Strauss syndrome, these patterns reflect autoantibodies to two lysosomal granule enzymes: serine protease-3 (PR3) and myeloperoxidase (MPO), respectively. Upon immunofluorescence testing of sera, many patients with other forms of inflammatory disease (e.g., SLE, autoimmune hepatitis, inflammatory bowel disease) have positive ANCA assays. ELISA testing in such patients, however, reveals antibody specificities for antigens other than PR3 and MPO. ANCA directed against PR3 and MPO are termed PR3-ANCA and MPO-ANCA, respectively.

## Method

To identify C- and P-ANCA patterns of immunofluorescence, ethanol- or formalin-fixed human neutrophils are coated with the patient's serum and stained with labeled anti-IgG. Formalin fixation is preferred because the presence of antinuclear antibodies may cause a false-positive P-ANCA pattern on ethanol-fixed cells.

One common laboratory approach is to screen with ethanol-fixed cells and to perform assays on formalin-fixed cells if immunofluorescence is observed on screening. Increasingly reliable ELISA assays for the detection of both PR3 and MPO have been available since the early 1990s. For optimal clinical utility, any positive immunofluorescence assay should be confirmed by the performance of anti-PR3 and -MPO ELISAs.

## Interpretation

The combination of C-ANCA and PR3-ANCA has a high positive predictive value for ANCA-associated vasculitis, particularly Wegener's granulomatosis. Similarly, the combination of P-ANCA and MPO-ANCA has a high positive predictive value for microscopic polyangiitis. (For further discussion of the role of ANCA assays in these diseases and in the Churg–Strauss syndrome, please see Chapter 21C.)

The more active and extensive the vasculitis, the more likely are ANCA assays to be positive. ANCA

titers often normalize with treatment but do not always do so, even if clinical remissions are achieved. Some data suggest that a persistent rise in ANCA titer or return of ANCA positivity heralds an increased risk of recurrent disease, but neither persistently positive ANCA tests nor rising ANCA titers provide reliable information about the timing of a disease flare. Treatment decisions in ANCA-associated vasculitis are never based entirely ANCA assay result. Moreover, positive ANCA tests may be caused by infection, drugs (particularly thyroid medications such as propylthiouracil), and, as noted, other autoimmune diseases. Thus, under most clinical circumstances, tissue biopsy remains the gold standard for diagnosis (13).

## COMPLEMENT

The complement cascade is a tightly regulated complex of proenzymes, regulatory proteins, and cell-surface receptors that mediate and augment both of complement the humoral and cellular immune response. Activation by antigen-immune complexes, bacterial surface proteins, and polysaccharides begins a fixed sequence of reactions that lead to increased vascular permeability, chemotaxis, cell lysis, antigen-immune complex clearance, and opsonization. The classical pathway (C1, C4, C2), the alternative pathway (factors B, D, and properdin), and the mannose-binding lectin pathway all share the final step of cleaving C3. The released product (C3b) then induces formation of the terminal membrane attack complex (C5–C9) (14).

### Method

Serum levels of individual components such as C3 and C4 are measured by ELISA and nephelometry. The plasma total hemolytic complement assay, or CH50, assesses the functional integrity of the classical pathway. Serum is diluted and added to sheep antibody-coated RBCs. The value reported is the reciprocal of the highest dilution able to lyse 50% of the RBCs.

### Interpretation

Decreased serum levels of individual components, especially C3 and C4, correlate with the increased consumption observed in active immune complex mediated disease, for example, SLE. In contrast, most inflammatory disorders that are not associated with immune complex deposition demonstrate elevated levels of complement because these proteins are acute phase reactants. Hypocomplementemia, though useful in narrowing the differential diagnosis, is generally not specific for any particular disease. C4 levels that are disproportionately low compared to those of C3 may

indicate the presence of cryoglobulins. Unfortunately, the correlations between changes in complement levels and disease activity are poor. In addition, hypocomplementemia may also be secondary to nonrheumatic diseases, notably subacute bacterial endocarditis and poststreptococcal glomerulonephritis (15). Low or undetectable CH50 may indicate a deficiency of one or more complement components. Patients with genetic deficiencies of early complement components (C1–C4) are at increased risk for developing immune-complex diseases (16), particularly some forms of SLE.

## CRYOGLOBULINS

Cryoglobulins are immunoglobulins that precipitate reversibly at cold temperatures. In a variety of diseases, cryoglobulins often bind with complement proteins and other peptides to form immune complexes. Based on their composition, cryoglobulins are classified into three types. Type I cryoglobulins are monoclonal immunoglobulins, frequently of the IgM isotype. Type II cryoglobulins are a mixture of polyclonal IgGs and monoclonal IgM. Type III cryoglobulins are a combination of polyclonal IgGs and polyclonal IgMs. In both type II and type III cryoglobulinemia, the IgM component has RF activity (i.e., it binds to the Fc portion of IgG), accounting for the fact that essentially all patients with these disorders are RF positive (often creating confusion in diagnosis with RA) (17).

### Method

For proper collection of cryoglobulins, careful attention to detail and preparation in advance are required. Whole blood must be drawn and maintained at body temperature until it coagulates. The sample is then centrifuged and the clot removed. The remaining serum is allowed to stand at 4°C for up to several days until precipitation is observed. The sample is spun again and the cryocrit is measure in a calibrated tube. Isotype and clonality are established by various immunochemical techniques.

### Interpretation

Cryoglobulins are not specific for any one disease. Type I cryoglobulins do not activate the complement cascade and are therefore associated with normal complement levels. They are linked to lymphoproliferative disorders, malignancies, and hyperviscosity syndromes, and often associated with sludging in the small vasculature of the extremities, eye, or brain. Type II and type III cryoglobulins, able to bind complement, are associated with hepatitis C virus infections and a syndrome of small vessel vasculitis (see Chapter 21D) (18).

## REFERENCES

1. Sox HC Jr, Liang MH. The erythrocyte sedimentation rate: guidelines for rational use. *Ann Intern Med* 1986; 104:515–523.
2. Miller A, Green M, Robinson D. Simple rule for calculating normal erythrocyte sedimentation rate. *BMJ* 1983; 286:266.
3. Bridgen M. The erythrocyte sedimentation rate. Still a helpful test when used judiciously. *Postgrad Med* 1998; 103:257–262.
4. Morley JJ, Kushner I. Serum C-reactive protein levels in disease. *Ann N Y Acad Sci* 1982;389:406–418.
5. Wener MH, Daum PR, McQuillan GM. The influence of age, sex and race on the upper limit of serum C-reactive protein concentration. *J Rheumatol* 2000;27:2351–2359.
6. Johsson T, Valdimarsson H. Is measurement of rheumatoid factor isotypes clinically useful? *Ann Rheum Dis* 1993;52:161–164.
7. Witherington RH, Teitsson I, Valdimarsson H, et al. Prospective study of early rheumatoid arthritis. II Association of rheumatoid factor isotypes with fluctuations in disease activity. *Ann Rheum Dis* 1984;43:679–685.
8. Vossenaar ER, Smeets TJ, Kraan MC, et al. The presence of citrullinated proteins is not specific for rheumatoid arthritis. *Arthritis Rheum* 2004;50:3485–3494.
9. Zendman AJW, Van Venroij, Pruijn GJM. Use and significance of anti-CCP autoantibodies in rheumatoid arthritis. *Rheumatology* 2006;45:20–25.
10. Niewold TB, Harrison MJ, Paget SA. Anti-CCP antibody testing as a diagnostic and prognostic tool in rheumatoid arthritis. *QJM* 2007;100:193–201.
11. Tan E, Feltkamp TE, Smolen JS, et al. Range of antinuclear antibodies in “healthy” individuals. *Arthritis Rheum* 1997;40:1612–1618.
12. Lyon R, Sonali N. Effective use of autoantibody tests in the diagnosis of systemic lupus erythematosus. *Ann N Y Acad Sci* 2005;1050:217–228.
13. Bartunkova J, Tesar V, Sediva A. Diagnostic and pathogenic role of antineutrophil cytoplasmic autoantibodies. *Rheumatology (Oxford)* 2003;106:73–82.
14. Walport MJ. Advances in immunology: complement. *N Engl J Med* 2001;344:1058–1066, 1140–1144.
15. Egner W. The use of laboratory tests in the diagnosis of SLE. *J Clin Pathol* 2000;53:424–432.
16. Ratnoff WD. Inherited deficiencies of complement in rheumatologic diseases. *Rheum Clin North Am* 1996;22: 1–21.
17. Brouet JC, Clauvel JP, Danon F, et al. Biological and clinical significance of cryoglobulins: a report of 86 cases. *Am J Med* 1974;57:775–788.
18. Ferri C, Zignego AL, Pileri SA. Cryoglobulins. *J Clin Pathol* 2002;55:4–13.

# Evaluation of the Patient

## C. Arthrocentesis, Synovial Fluid Analysis, and Synovial Biopsy

KENNETH H. FYE, MD

- When the diagnosis of an inflammatory arthropathy is unclear, synovial fluid should be evaluated for the three Cs: cell count, culture, and crystals.
- Removal of infected synovial fluid is often a critical adjunct to antibiotics in the treatment of a septic joint.
- Careful preparation, appropriate assistance, and planning of the approach to the joint enhance the likelihood of success in performing arthrocentesis.
- Synovial fluid neutrophil counts in excess of 100,000/mm<sup>3</sup> spells an infection until proven otherwise, and should be treated empirically with antibiotics until the results of culture are available.
- Microcrystalline disorders (gout and pseudogout) occasionally lead to synovial fluid neutrophil counts >100,000/mm<sup>3</sup>.
- Examination of synovial fluid under polarized microscopy is the only way of securing the diagnosis of a microcrystalline disease.

Despite the development of increasingly sophisticated serologic tests and imaging techniques, synovial fluid (SF) analysis remains one of the most important diagnostic tools in rheumatology (1). Normal SF lubricates the joint and, along with blood vessels in subchondral bone, supplies nutrients to the avascular articular cartilage. The majority of SF constituents originate in the subsynovial vasculature, diffusing through the synovium into the joint space. However, certain important macromolecules, such as hyaluronic acid and lubricin, are synthesized and secreted by synoviocytes (which line the joint). Plasma proteins not found in SF include prothrombin, fibrinogen, factor V, factor VII, antithrombin, large globulins, and some complement components (2).

Synovial fluid protein concentrations reflect the interplay between plasma concentration, synovial fluid blood flow, endothelial cell permeability, and lymphatic drainage. There are few cells in normal SF. In arthritis, invading inflammatory cells produce additional proteins and release activated cytokines into SF. Elevated intra-articular pressure due to increased amounts of SF leads to diminished perfusion of synovial microvasculature, disrupting the process of diffusion that supplies synovial nutrients (3). In addition, offending substance such as microorganisms, foreign bodies, or abnormal crystals,

may be present. Analyzing SF may yield information invaluable in making the diagnosis, determining prognosis, and formulating appropriate therapy in patients with arthritis (4).

## ARTHROCENTESIS

### Indications

An acute, inflammatory, monoarticular arthritis should be considered either infectious or crystal-induced until proven otherwise. Arthrocentesis is the only method of identifying infection or crystal-induced disease unequivocally. Because acute bacterial infections can lead rapidly to joint and bone destruction, arthrocentesis must be performed immediately if there is any suspicion of infection. If preliminary analysis of the SF is compatible with infection—that is, the white blood cell (WBC) count is markedly elevated but no crystals are identified—antibiotic therapy should be initiated pending definitive culture results. SF analysis can confirm the presence of crystal-induced arthritis and enable the clinician to identify the culprit crystal precisely. If a polarized microscope is used, the sensitivity of SF analysis for identifying a crystal-induced arthropathy is 80% to 90%



(4). Trauma can sometimes result in an acute monarticular arthropathy. Analysis of joint fluid is the only way to distinguish posttraumatic hemarthrosis from posttraumatic arthritis with bland synovial fluid.

Arthrocentesis can also be useful in the evaluation of chronic or polyarticular arthropathies. SF analysis enables the clinician to differentiate inflammatory and noninflammatory arthritides. The procedure is often essential in distinguishing chronic crystal-induced arthritide such as polyarticular gout or calcium pyrophosphate dehydrate deposition disease from other arthropathies, such as rheumatoid arthritis (RA). Although chronic mycobacterial or fungal infections can sometimes be identified in SF, synovial biopsy is frequently necessary to distinguish indolent infections from other unusual chronic inflammatory processes, such as pigmented villonodular synovitis. Because people with chronic inflammatory arthropathies (e.g., RA) have an increased susceptibility to infection, acute monarticular arthritis in a patient whose disease is otherwise well controlled is an indication for a diagnostic arthrocentesis.

The cellular and humoral components of inflammatory SF can damage articular and periarticular tissues (5). The activated enzymes in septic SF are highly destructive to cartilage. Thus, in a septic joint, repeated arthrocentesis may be necessary to minimize the accumulation of purulent material (6). If purulent SF reaccumulates despite repeated arthrocenteses, surgical arthroscopy with drain placement should be performed to ensure adequate drainage of the infected joint. For joints that are noninfected but inflamed, drainage of as much SF as possible removes inflammatory cells and other mediators, decreases intra-articular pressure, and reduces the likelihood of articular damage (7). Removal of inflamed fluid also increases the efficacy of intra-articular corticosteroids. Finally, blood in a joint, such as may occur in hemophilia, can lead quickly to adhesions that inhibit joint mobility. When clinically indicated, therefore, therapeutic arthrocentesis may be prudent in a patient with hemarthrosis. When contemplating such a procedure in a hemophiliac, careful consideration should be given to approaches to maximize hemostasis (e.g., the use of clotting factor VIII concentrate; see Chapter 25A) and prevent additional intra-articular bleeding as a result of the procedure.

## Techniques

### Sterile Procedures

Infections caused by arthrocentesis are very rare. Nevertheless, preventive measures to minimize the likelihood of postarthrocentesis infection are prudent. Betadine or povidone-iodine should be applied to the aspiration site and allowed to dry. Alcohol should then

be used to swab the area to prevent an iodine burn. Although it is wise to wear gloves during any procedure involving exposure to potentially infected body fluids, sterile gloves are generally not necessary. Sterile gloves should be used if the clinician anticipates having to palpate the target anatomy *after* preparation of the arthrocentesis site using antiseptic technique.

### Local Anesthesia

Local anesthesia with 1% lidocaine without epinephrine significantly reduces discomfort associated with the procedure. One-quarter to 1 cc of lidocaine is usually sufficient, depending on the joint being anesthetized. A 25- or 27-gauge needle should be used to infiltrate the skin, subcutaneous tissue, and pericapsular tissue. Larger caliber needles are more uncomfortable and can lead to local trauma. Although many clinicians apply ethyl chloride to the skin before injecting the anesthesia, others believe this practice is cumbersome and results in no clinically significant additional anesthesia.

After the periarticular tissues have been anesthetized, a 20- or 22-gauge needle can be used to aspirate small- to medium-sized joints. An 18- or 19-gauge needle should be used for aspirating large joints or joints suspected of infections, intra-articular blood, or viscous, loculated fluid. Small syringes are easier to manipulate and provide greater suction than large syringes, but must be changed frequently when aspirating large joints with copious amounts of SF. When using a large syringe to aspirate a significant amount of fluid, the suction in the syringe should be broken before use and the plunger drawn. Excessive negative pressure can suck synovial tissue into the needle and prevent an adequate joint aspiration. A Kelly clamp can stabilize the hub of the needle while removing a full syringe.

Typical landmarks are often obscured around a swollen joint. Therefore, after a thorough physical examination and before sterilizing and anesthetizing the skin, it is often helpful to mark the approach with a ballpoint pen. If landmarks are still obscure, use sterile gloves to maintain a clean field while using palpation to identify an aspiration site for the target joint. Many joints, such as the knee, ankle, and shoulder, are amenable to both medial or lateral approaches.

In contrast to joint injection, aspiration is performed most easily when a joint is in a position of maximum intra-articular pressure. For example, injection of the knee is best done with the knee in 90° flexion while the patient is seated at an examining table with the foot dangling. This position allows gravity to open the joint space, offering easy access to the intra-articular space from either side of the infrapatellar tendon. However, this position decreases intra-articular pressure, thereby decreasing the likelihood of a successful aspiration. Conversely, therefore, the optimal positioning of the

**TABLE 2C-1.** ANATOMIC APPROACH TO ASPIRATION.

JOINT	POSITION OF JOINT	LOCATION OF APPROACH
Knee	Extended	Medial or lateral under the patella
Shoulder	Neutral adduction, external rotation	Anterior: inferolateral to coracoid Posterior: under the acromion
Ankle	Plantar flexion	Anteromedial: medial to extensor hallucis longus Anterolateral: lateral to extensor digiti minimi
Subtalar	Dorsiflexion to 90°	Inferior to tip of lateral malleolus
Wrist	Midposition	Dorsal into radiocarpal joint
First carpometacarpal	Thumb abducted and flexed	Proximal to base of metacarpal
Metacarpophalangeal or interphalangeal	Finger slightly flexed	Just under extensor mechanism dorsomedial or dorsolateral
Metatarsophalangeal or interphalangeal	Toes slightly flexed	Dorsomedial or dorsolateral
Elbow	Flexed to 90°	Lateral in triangle formed by lateral epicondyle, radial head, and olecranon process

patient for aspiration of the knee is lying supine with the knee fully extended, thereby maximizing intra-articular pressure. Although most joints can be aspirated without radiologic assistance, some joints, such as the hips, sacroiliac joints, or zygoapophyseal joints, should be aspirated using computed tomography guidance. Aspirations should generally not be done through areas of infection, ulceration, or tumor, or obvious vascular structures. Table 2C-1 lists suggestions for optimal anatomic approaches for aspirating or injecting specific joints.

If corticosteroids are to be injected after aspiration is complete, the drug should be prepared in a separate syringe ahead of time so that the aspirating needle already in the joint can be used for the injection. If difficulties arise during the procedure, the needle should not be manipulated aggressively because of the risk of damaging the cartilage, capsule, or periarticular sup-

porting structures. If bone is encountered, slight withdrawal of the needle followed by redirection and another attempt at aspiration is indicated. In unsuccessful aspiration attempts, the needle may be outside the joint space, blocked by synovium or SF debris, or too small for the degree of SF viscosity.

## SYNOVIAL FLUID ANALYSIS

The four general classes of SF, defined by differences in gross examination, total and differential WBC count, the presence or absence of blood, and the results of culture are shown in Table 2C-2. SF characteristics of arthritic conditions can be extremely variable and may change with therapy. Therefore, the classes of SF are

**TABLE 2C-2.** CLASSES OF SYNOVIAL FLUID.

	CLASS I (NONINFLAMMATORY)	CLASS II (INFLAMMATORY)	CLASS III (SEPTIC)	CLASS IV (HEMORRHAGIC)
Color	Clear/yellow	Yellow/white	Yellow/white	Red
Clarity	Transparent	Translucent/opaque	Opaque	Opaque
Viscosity	High	Variable	Low	NA
Mucin clot	Firm	Variable	Friable	NA
WBC count	<2,000	2,000–100,000	>100,000	NA
Differential	<25% PMNs	>50% PMNs	>95% PMNs	NA
Culture	Negative	Negative	Positive	Variable

ABBREVIATIONS: PMN, polymorphonuclear leukocytes; NA, not applicable.

**TABLE 2C-3. DIAGNOSIS BY SYNOVIAL CLASS.**

CLASS I	CLASS II	CLASS III	CLASS IV
Osteoarthritis	Rheumatoid arthritis	Septic arthritis (bacterial)	Trauma
Traumatic arthritis	Systemic lupus erythematosus		Pigmented villonodular synovitis
Osteonecrosis	Poly/dermatomyositis		Tuberculosis
Charcot's arthropathy	Scleroderma		Neoplasia
	Systemic necrotizing vasculitides		Coagulopathy
	Polychondritis		Charcot's arthropathy
	Gout		
	Calcium pyrophosphate deposition disease		
	Hydroxyapatite deposition disease		
	Juvenile rheumatoid arthritis		
	Ankylosing spondylitis		
	Psoriatic arthritis		
	Reactive arthritis		
	Chronic inflammatory bowel disease		
	Hypogammaglobulinemia		
	Sarcoidosis		
	Rheumatic fever		
	Indolent/low virulence infections (viral, mycobacterial, fungal, Whipple's disease, Lyme disease)		

intended only as a general guide in the diagnosis of arthritis (Table 2C-3).

## Gross Examination

Certain characteristics of SF provide the clinician with valuable clues as to the nature of an arthropathy. Clarity reflects the density of particulate matter in SF. Normal SF or that from patients with osteoarthritis is colorless and clear. In contrast, the SF of systemic lupus erythematosus (SLE) or mild rheumatoid arthritis may be translucent, and the SF from a septic joint will be opaque. Generally, the number of WBCs determines the opacity of inflammatory SF (8). The xanthochromia that sometimes characterizes SF from patients with arthritis is caused by the breakdown of heme from red blood cells that leak into the joint space from diseased synovium. Gross, fresh bleeding due to trauma, hemophilia, pigmented villonodular synovitis, or other pathologic processes will result in red or bloody SF. Other materials that can opacify SF include lipids, crystals (such as calcium pyrophosphate dehydrate, monosodium urate, or hydroxyapatite), and debris that accumulates in destructive forms of arthritis (such as severe RA or Charcot's arthropathy).

Normal joint fluid is viscous due to the presence of hyaluronan. Enzymes present in inflammatory arthropathies digest hyaluronic acid, resulting in a decrease in fluid viscosity. When a single drop of normal SF is expressed from a syringe, a tail or string of fluid should stretch approximately 10 cm before surface tension is broken. The greater the degree of inflammation within a joint, the higher the number of inflammatory cells and the greater the concentration of activated enzymes that

break down hyaluronan. The string formed by inflammatory SF may be only 5 cm or less. Extremely viscous fluid with a very long string is suggestive of hypothyroidism (9). One can also determine the integrity of hyaluronic acid by placing a few drops of SF into 2% acetic acid. Normal SF will form a stable clump of hyaluronate-protein complex called a *mucin clot*. Inflammatory SF fluid forms a mucin clot that will fragment easily, reflecting the loss of integrity of hyaluronan.

## Cell Count

The WBC count and differential are among the most valuable diagnostic characteristics of SF. Normal SF contains fewer than 200 cells/mm<sup>3</sup>. SF from noninflammatory arthropathies may have WBC counts of up to 2000 cells/mm<sup>3</sup> (9). Noninfectious inflammatory arthropathies have WBC counts that vary widely, ranging from 2000 to 100,000 cells/mm<sup>3</sup> (10). Although the autoimmune arthropathies generally present with WBC counts of 2000 to 30,000 cells/mm<sup>3</sup>, cell counts of 50,000/mm<sup>3</sup> or higher are not unusual in RA. Patients with crystal-induced arthritis, such as acute gout, usually have WBC counts of greater than 30,000 cells/mm<sup>3</sup> and counts of 50,000 to 75,000 cells/mm<sup>3</sup> are common. The closer the WBC count gets to 100,000 cells/mm<sup>3</sup>, the greater the likelihood of a septic arthritis. Although a rare patient with crystal-induced arthropathy, RA, or even a seronegative arthropathy may have a WBC count greater than 100,000 cells/mm<sup>3</sup>, such patients should be treated empirically for a septic joint until microbiologic data exclude infection.

A WBC count of less than 100,000 cells/mm<sup>3</sup> does not preclude the possibility of infection. Patients with

chronic inflammatory arthritides due to RA, SLE, or psoriatic arthritis have an increased risk of joint sepsis secondary to both the structural joint damage caused by chronic inflammation and the immunosuppressive effects of many of the drugs used to treat those diseases. Moreover, many disease modifying agents in such diseases, including methotrexate, cyclosporine, leflunomide, azathioprine, cyclophosphamide, or other cytotoxic agents, may blunt the WBC response to infection and cause spuriously low WBC counts within the SF. In comparison with bacterial infections, more indolent processes such as tuberculosis or fungal infection are associated with lower WBC counts; SF counts  $<50,000/\text{mm}^3$  are typical.

The differential WBC count can provide valuable information (11). SF from a septic joint usually contains greater than 95% polymorphonuclear leukocytes (PMNs). Frequently, more than 90% of the WBC in the SF from patients with crystal-induced arthropathies or RA will be PMNs, as well. On the other hand, the differential WBC count of noninflammatory SF characteristically contains less than 50% granulocytes.

Examination of a wet preparation is particularly helpful in assessing SF for its cellular and crystalline content. The wet preparation is best done on SF applied directly from the syringe to a slide, but SF anticoagulated with sodium heparin or EDTA can also be used. Ragocytes, which are PMNs with refractile inclusions containing immune complexes and complement, can be observed on wet-preparation examination of SF from patients with RA. SF from patients with SLE may contain lupus erythematosus (LE) cells. Cytologic examination may reveal malignant cells in the SF of patients with synovial metastases.

## Blood

The presence of blood in a joint is usually the result of acute trauma. If arthrocentesis reveals a hemarthrosis, the bloody fluid should be evacuated to prevent synovial adhesions that could decrease the range of motion of the injured joint. Hemarthrosis is sometimes seen in Charcot's arthropathy because of chronic trauma to the affected joint. In the absence of a history of trauma, bloody SF could represent a traumatic aspiration. The blood seen in a traumatic aspiration is not homogeneous throughout the sample and usually appears only after the clinician encounters difficulty with the procedure. If the procedure was not traumatic, the presence of bloody SF should alert the clinician to several possibilities. Recurrent hemarthrosis is common in people with severe coagulation disorders such as hemophilia, von Willebrand's disease, and platelet disorders, and in patients on anticoagulation therapy. The SF from patients with pigmented villonodular synovitis is virtually always hemorrhagic or xanthochromic. In fact, the

pigmentation derives from hemosiderin accumulated from recurrent hemorrhage. The SF from patients with tuberculosis is often hemorrhagic, as is that associated with local or metastatic tumors. Patients with congenital, metastatic, or hemorrhagic disorders, such as Ehlers–Danlos syndrome, pseudoxanthoma elasticum, sickle cell disease, or scurvy, may also develop hemarthrosis.

## Crystals

Although crystals can be identified in SF that is a few days old, optimal examinations for crystals are performed on fresh SF prepared immediately after aspiration (12). If the SF is to be anticoagulated before examination, only sodium heparin and EDTA are acceptable; lithium heparin and calcium oxalate may both form birefringent crystals that can confound the fluid examination. In addition, a clean slide and cover slip should be used, because talc, dust, or other debris may mimic crystalline materials.

Although monosodium urate crystals can be seen with ordinary light microscopy (13), an adequate crystal examination requires a polarized light microscope with a red compensator (14). The lower polarizing plate (the polarizer), inserted between the light source and the study specimen, blocks all light waves except those that vibrate in a single direction. The second polarizing plate (the analyzer) is positioned between the study specimen and the observer and is oriented  $90^\circ$  from the polarizer. No light passes through to the observer, who sees only a dark field through the microscope. Birefringent material will bend light waves that have passed through the polarizer, so they can pass through the analyzer to the observer, who now sees a white object against a dark field. If a first order red compensator is placed between the polarizer and the analyzer, the background field becomes red and a birefringent crystal becomes yellow or blue, depending on its identity and orientation to the direction of the slow-vibration axis of the light passing through the red compensator.

Light passing through the red compensator is refracted into two vibration waves, a fast wave and a slow wave, which are perpendicular to each other. The identical phenomenon occurs with light passing through a birefringent crystal. The fast-wave vibration of monosodium urate, which is a birefringent crystal, is oriented along the long pole of the needle-shaped crystal. When the long pole of a monosodium urate crystal is parallel to the slow-wave axis marked on the red compensator, a color-subtraction interference pattern of fast and slow vibration occurs, resulting in a yellow color. A crystal that is yellow when its long pole is parallel to the slow axis of vibration of the red compensator is, by convention, considered to be negatively birefringent. If the slow wave of vibration of a birefringent crystal is



parallel to its long pole when the long pole of the crystal is parallel to the slow axis of the red compensator, an addition pattern of slow-plus-slow vibration will result in a blue color. By convention, a birefringent crystal that is blue when the long pole is parallel to the slow axis of vibration of the red compensator is considered to be positively birefringent. Calcium pyrophosphate dehydrate crystals, for example, are positively birefringent. Birefringence can be strong, meaning the birefringent crystal is bright and easy to see, or weak, meaning the birefringent crystal is muted and difficult to detect.

Crystals are identified by a combination of shape and birefringence characteristics. Monosodium urate crystals are needle shaped and have strong, negative birefringence (see Figure 12A-7). In contrast, calcium pyrophosphate dehydrate crystals are short and rhomboid, and show weak, positive birefringence. Calcium oxalate crystals, which can be seen in primary oxalosis or in chronic renal failure, are rod or tetrahedron shaped and positively birefringent. Cholesterol crystals are flat and boxlike, tend to stack up, and often have notched corners. Spherules with birefringence in the shape of a Maltese cross generally represent lipid. However, it has been suggested that some forms of urate or apatite may take this shape (15,16). Hydroxyapatite is usually difficult to recognize in SF, partly because it is not birefringent. However, sometimes it forms clumps large enough to be seen when stained with alizarin red S. Finally, glucocorticoid crystals injected into the joint as a therapeutic measure are birefringent and may be misinterpreted by the unwary observer.

The presence of intracellular crystals is virtually diagnostic of a crystal-induced arthropathy. However, a superimposed infection must be excluded even if crystals are identified. In addition, a patient may have more than one crystal-induced disorder. For example, up to 15% of patients with gout also have calcium pyrophosphate dihydrate deposition disease. It is important to make that determination, because it will affect therapy. A patient with chronic gout may require only ongoing hypouricemic therapy (and perhaps prophylactic colchicine). In contrast, a patient with both gout and calcium pyrophosphate dihydrate deposition disease may require continued nonsteroidal anti-inflammatory therapy in addition to ongoing hypouricemic therapy.

Attempts to aspirate inflammatory joints are not always successful. For example, aspiration of an inflamed first metatarsophalangeal joint is difficult. However, if the clinician keeps negative pressure on the syringe as the needle is withdrawn from articular or periarticular tissues, there is almost always enough interstitial fluid in the needle to allow adequate polarized-light examination for crystals. Simply remove the needle from the syringe, fill the syringe with air, reattach the needle, and

use the air to blow the fluid in the needle onto a slide. This is a particularly valuable technique when looking for monosodium urate crystals in podagra.

## Culture

An inflammatory monarticular arthritis should be considered infectious until proven otherwise. In most bacterial infections, Gram stain and culture and sensitivity yield valuable diagnostic information and are crucial components of analysis. Generally, SF need only be collected in a sterile culture tube and transported to the laboratory for routine analysis. Unfortunately, some important infectious agents are difficult to culture, so negative Gram stains and cultures do not necessarily preclude an infection. For example, SF cultures are negative in more than two-thirds of people with gonococcal arthritis, even if chocolate agar is used as the culture medium. In addition, tuberculosis is often difficult to culture from SF, and special techniques and culture media are required for anaerobic or fungal pathogens. Sometimes mycobacterial (17) or fungal (18) infections can be detected only on synovial biopsy material. Because bacterial infections can lead rapidly to joint destruction, early antibiotic therapy is essential. Antibiotic therapy should be initiated based on the results of WBC count, WBC differential, and Gram stain, and adjusted later if necessary, based on the results of culture and sensitivity.

## SYNOVIAL BIOPSY

Arthroscopy has greatly facilitated the clinician's ability to obtain synovial tissue for analysis. At one time, synovial tissue could only be obtained by open arthrotomy or blind needle biopsy (19). Advances in the technology of arthroscopy have led to the development of small, flexible instruments that allow direct visualization and biopsy of synovium (20). In certain clinical settings, synovial biopsy can add significant diagnostic information.

The granulomatous diseases are frequently difficult to diagnose by SF analysis alone. SF acid-fast smears and cultures are negative in a significant number of patients with tuberculosis. The diagnosis of tuberculous arthritis is often based on histologic demonstration of caseating granulomata and acid-fast stain or culture evidence of *Mycobacterium tuberculosis* in synovial tissue. Atypical mycobacterial and fungal arthropathies can be indolent, inflammatory, oligoarticular infections that cannot be diagnosed without obtaining synovial tissue for histologic and microbiologic analysis (18). In patients without pulmonary involvement, the diagnosis of sarcoid arthropathy may rest on the demonstration of noncaseating granulomata in synovial tissue.

Malignant infiltrations of the synovium can be seen in synovial sarcomas, lymphomas, metastatic disease, and leukemias. The diagnosis of synovial osteochondromatosis can be made based on the presence of foci of osteometaplasia or chondrometaplasia on synovial biopsy. Sometimes cytologic examination of SF reveals a malignancy. However, the diagnosis of a malignant arthropathy is generally based upon histologic demonstration of malignant cells in synovial tissue. Therefore, synovial biopsy is indicated if there is a suspicion of articular malignancy.

The diagnosis of some infiltrative nonmalignant processes depends on the histologic or microscopic evaluation of synovial material. A diagnosis of amyloid arthropathy can be made if apple green birefringence is observed in Congo red–stained synovial biopsy material examined under polarized light. Hemochromatosis is characterized by the deposition of golden brown hemosiderin in synovial lining cells. Hydroxyapatite deposits in synovial tissue appear as clumps of material that stain with alizarin red S and have a typical appearance on electron micrography. The synovium of patients with multicentric reticulohistiocytosis is filled with multinucleated giant cells and histiocytes with a granular ground-glass appearance. The SF from patients with ochronosis has a ground-pepper appearance due to pigmented debris. The synovial biopsy from these patients contains shards of ochronotic pigment that is diagnostic. In Whipple's disease, foamy macrophages containing periodic acid-Schiff (PAS)–positive material can be seen on synovial biopsy. Pigmented villonodular synovitis is defined by the presence of giant cells, foamy cells, and hemosiderin deposits in synovial tissue.

The ease of direct biopsy of target tissues that has resulted from advances in arthroscopic techniques has not changed the clinical indications for synovial biopsy. Biopsy should be done only if the diagnosis cannot be made using traditional, less invasive procedures.

## REFERENCES

- Swan A, Amer H, Dieppe P. The value of synovial fluid assays in the diagnosis of joint disease: a literature survey. *Ann Rheum Dis* 2002;61:493–498.
- Gatter RA, Schumacher HR Jr. *A practical handbook of joint fluid analysis*, 2nd ed. Philadelphia: Lea & Febiger; 1991.
- Gaffney K, Williams RB, Jolliffe VA, Blake DR. Intra-articular pressure changes in rheumatoid and normal peripheral joints. *Ann Rheum Dis* 1995;54:670–673.
- Shmerling RH. Synovial fluid analysis. A critical appraisal. *Rheum Dis Clin North Am* 1994;20:503–512.
- Chapman PT, Yarwood H, Harrison AA, et al. Endothelial activation in monosodium urate monohydrate crystal-induced inflammation. *Arthritis Rheum* 1997;40:955–965.
- Sack KE. Joint aspiration and injection: a how-to guide. *J Musculoskel Med* 1999;16:419–427.
- Zuber TJ. Knee joint aspiration and injection. *Am Fam Physician* 2002;66:1497–1507.
- Pasqual E, Jovani V. Synovial fluid analysis. *Best Pract Res Clin Rheumatol* 2005;19:371–386.
- Dorwart BB, Schumacher HR. Joint effusions, chondrocalcinosis and other rheumatic manifestations in hypothyroidism. A clinicopathologic study. *Am J Med* 1975;59:780–790.
- Krey PR, Bailen DA. Synovial fluid leukocytosis. A study of extremes. *Am J Med* 1979;67:436–442.
- Trampuz A, Hanssen AD, Osmon DR, et al. Synovial fluid leukocyte count and differential for the diagnosis of prosthetic knee infection. *Am J Med* 2004;117:556–562.
- Kerolus G, Clayburne G, Schumacher HR. Is it mandatory to examine synovial fluids promptly after arthrocentesis? *Arthritis Rheum* 1989;32:271–278.
- Gordon C, Swan A, Dieppe A. Detection of crystals in synovial fluid by light microscopy: sensitivity and reliability. *Ann Rheum Dis* 1989;48:737–742.
- Joseph J, McGrath H. Gout or “pseudogout”: how to differentiate crystal-induced arthropathies. *Geriatrics* 1995;50:33–39.
- McCarty DJ, Halverson PB, Carrera GF, Brewer BJ, Kozin F. “Milwaukee shoulder”—association of microspheroids containing hydroxyapatite crystals, active collagenase, and neutral protease with rotator cuff defects. *Arthritis Rheum* 1981;24:464–473.
- Beaudet F, de Medicis R, Magny P, Lussier A. Acute apatite podagra with negatively birefringent spherulites in the synovial fluid. *J Rheumatol* 1993;20:1975–1978.
- Sequeira W, Co H, Block JA. Osteoarticular tuberculosis: current diagnosis and treatment. *Am J Ther* 2000;7:393–398.
- Kohli R, Hadley S. Fungal arthritis and osteomyelitis. *Infect Dis Clin North Am* 2005;19:831–851.
- Schumacher HR, Kulka JP. Needle biopsy of the synovial membrane—experience with the Parker-Pearson technic. *N Engl J Med* 1972;286:416–419.
- Gerlag D, Tak PP. Synovial biopsy. *Best Pract Res Clin Rheumatol* 2005;19:387–400.

# Evaluation of the Patient

## D. Imaging of Rheumatologic Diseases

WILLIAM W. SCOTT, JR., MD

WILLIAM J. DIDIE, MD

LAURA M. FAYAD, MD

- Conventional radiographs are the initial imaging agent of choice for most rheumatic conditions. For most forms of arthritis, no additional imaging studies are required.
- Trabecular bone and small bone erosions are visualized well by conventional radiography.
- Weight-bearing views of the knees are important in the evaluation of significant knee osteoarthritis.
- Computed tomography (CT) is superior to conventional radiographs in the assessment of certain joint conditions, including many cases of tarsal coalition, sacroiliitis, osteonecrosis, and sternoclavicular joint disease.
- High resolution CT of the lungs is an essential adjunct to the evaluation of many inflammatory rheumatic diseases, for example, systemic sclerosis, systemic vasculitis, and other disorders associated with signs of interstitial lung disease.
- Magnetic resonance imaging (MRI), which has superior imaging capabilities of soft tissue and bone marrow lesions, is the study of choice for a host of musculoskeletal diagnoses, including meniscal tears of the knee, spinal disc herniations, osteonecrosis, osteomyelitis, skeletal neoplasms, and others.
- Bone densitometry plays a crucial role in the diagnosis and treatment of osteopenia and osteoporosis.

Imaging techniques may aid in making diagnoses, permit objective assessments of disease severity and response to treatment, and promote new understandings of disease processes. Imaging modalities that are valuable in rheumatology include conventional radiography, computed tomography (CT), magnetic resonance imaging (MRI), ultrasound, radionuclide imaging, arthrography, bone densitometry, and angiography.

A basic knowledge of the merits and limitations of these techniques is essential in selecting the most appropriate and cost-effective imaging. In the discussion to follow, *high spatial resolution* will indicate excellent ability of an imaging modality to demonstrate fine bone detail and to detect small calcifications. *High contrast resolution* will indicate excellent ability to distinguish different soft tissue structures. Techniques such as conventional radiography have good spatial resolution. MRI generally has best contrast resolution among current imaging techniques. This chapter reviews the basic imaging techniques with regard to their spatial and contrast resolution (which determine the degree to

which individual structures are visualized), radiation dose to the patient, availability, and specific uses in assessing musculoskeletal signs and symptoms.

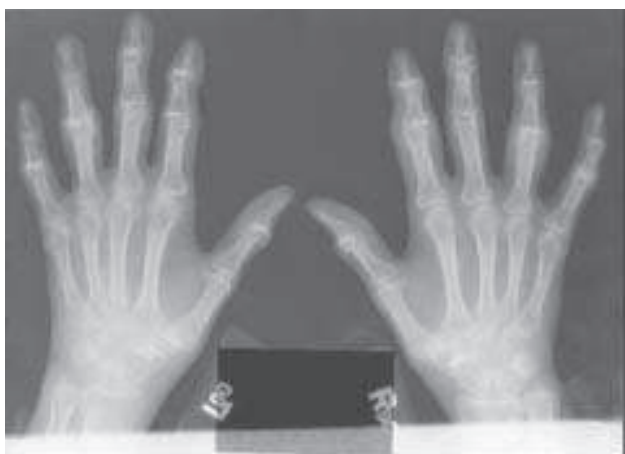### CONVENTIONAL RADIOGRAPHY

Conventional radiographs are the starting point for most imaging evaluations in rheumatic disorders, even when studies such as MRI are expected to follow. The cost is low and spatial resolution is very high, permitting good visualization of trabecular detail and tiny bone erosions. When necessary, resolution can be enhanced further by magnification techniques and film–screen combinations optimized for detail. However, contrast resolution is poor compared to that obtainable with CT and MRI. This limitation is especially noticeable when trying to evaluate soft tissues. Although plain radiography is a useful tool to assess the effect of a soft tissue mass on nearby bone and to detect calcification within

soft tissue, other techniques should be employed if optimal soft tissue imaging is required.

Examination of peripheral structures, such as the hands and feet, delivers a low radiation dose to the patient. Serial studies of the extremities can be performed without concern about excessive radiation exposure. Studies of central structures, however, such as the lumbar spine and pelvis, expose patients to high radiation doses. Close proximity to the gonads and to bone marrow increases the potentially detrimental effects to the patient. Whenever possible, the pelvic region of pregnant or potentially pregnant women should not be exposed to x-rays, and radiation to children should be minimized stringently. When such studies are necessary in these patients, radiation physicists can calculate the minimum radiation dose required for the imaging study. These same basic principles apply to all other x-ray imaging techniques.

Conventional radiography is widely available and convenient. Moreover, a vast fund of knowledge about plain radiographic findings in various rheumatic diseases is available (Figures 2D-1–2D-3). In many cases, simple, low cost imaging may provide all the information necessary to make clinical decisions. If the plain radiograph of the shoulder shows upward subluxation of the humeral head so that it contacts the undersurface of the acromion, one can be quite certain that the rotator cuff is torn with atrophic musculature, and likely very difficult to repair (Figure 2D-4). This may argue against a decision to undertake surgery. If surgery is contemplated, however, then MRI can confirm the large size of the rotator cuff tendon tear, the extent of muscle



**FIGURE 2D-1**

Typical radiographic findings in osteoarthritis of the hand showing asymmetric joint narrowing with osteophyte formation. The distal interphalangeal joints, proximal interphalangeal joints, and first carpometacarpal joint are most commonly involved.

atrophy, and evaluate the state of the biceps tendon and articular cartilage in such cases.

Knee radiographs are useful in cases of advanced arthritis, when they may demonstrate complete loss of knee joint cartilage and bone-on-bone contact. This marks the end point for useful arthroscopic and medical treatment of knee arthritis and time to consider joint replacement. Weight-bearing views are necessary because hyaline cartilage loss is deduced from the degree of apposition of the bony surfaces. In this regard, the flexed posterior–anterior (PA) standing radiograph is often more useful than an anterior–posterior (AP) view in full extension, as the flexed view images the portion of the articular surface subject to the greatest wear (Figure 2D-5). However, for earlier stages of arthritis, MRI is important for detection of small focal articular cartilage defects that may potentially be treated with recently developed surgical techniques.

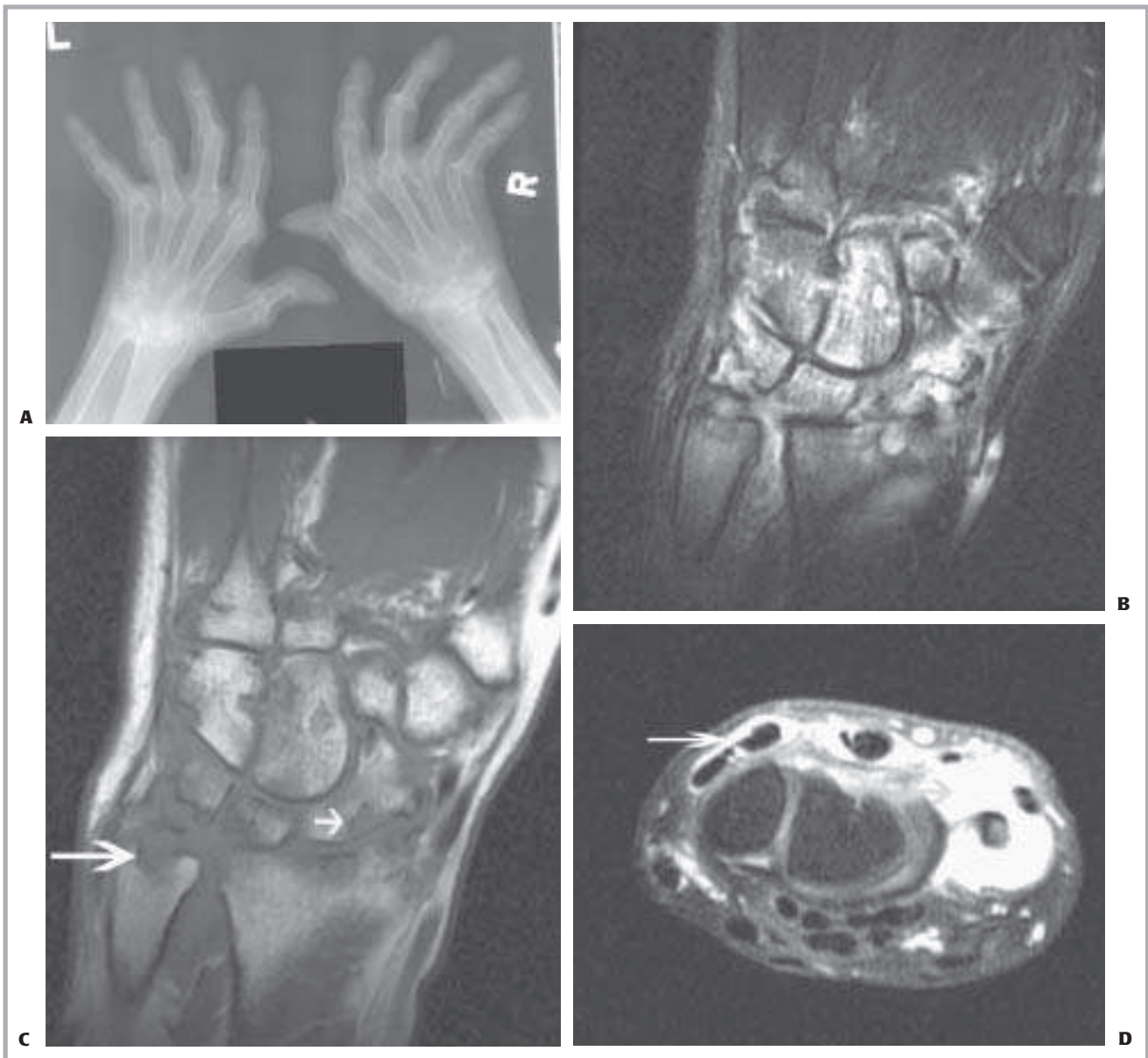## DIGITAL RADIOGRAPHY

Computed radiography uses a photosensitive phosphor plate to create a digital image, rather than the analog image of conventional radiography. At present, computed radiography images are utilized at most centers. The resolution is adequate for many routine joint evaluations and can be improved by magnification, if necessary for special tasks. The radiation dose is approximately the same as for conventional radiography. Soft tissue is better visualized than on conventional radiographs.

Direct radiography is a technique whereby digital images are created at the time of x-ray exposure. The advantages of digital images, whether digitized conventional radiographs, computed radiography, or direct radiography, include the ability to manipulate images electronically and to display images simultaneously in several remote areas. Image manipulation permits technically excellent final images to be obtained under adverse circumstances. For this reason, computed radiography is currently popular in emergency departments and intensive care units, locations where it is often difficult to obtain optimal radiographic exposures. The ability to manipulate digital data is also useful to researchers wishing to make automated measurements on radiographs and to clinicians wishing to send images via the Internet.

The resolution of computed radiography can be improved and conventional high resolution radiographs can be converted into digital format. CT, MRI, and ultrasound images are also acquired in digital form, and are easily transported and manipulated. Digital imaging, now widely utilized, has the advantages of rapid transmission, cost-effective storage, and easy retrieval.

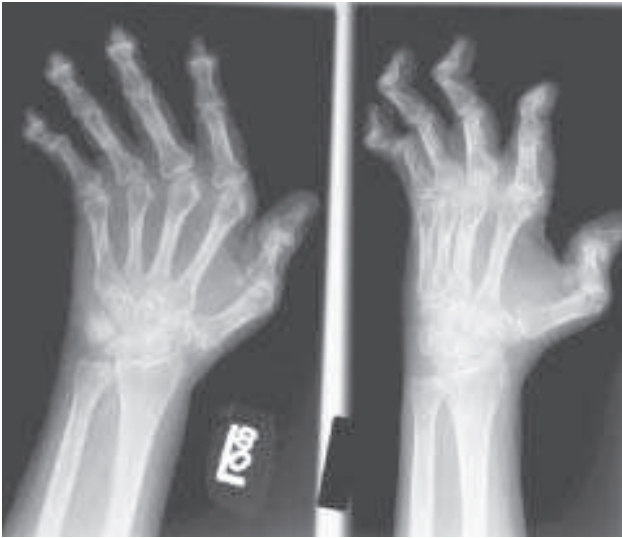



**FIGURE 2D-2**

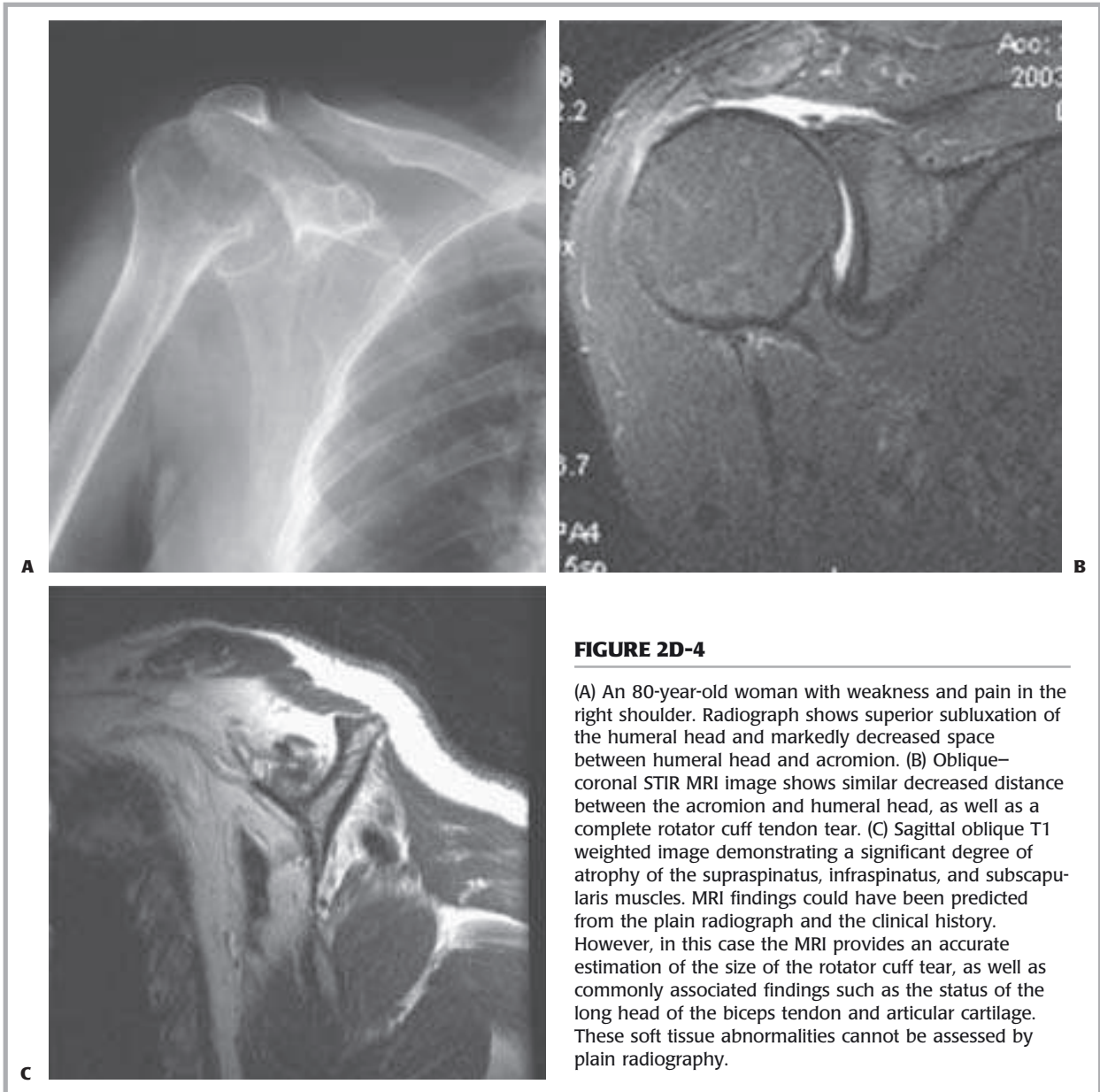
(A) Severe rheumatoid arthritis in an elderly woman showing erosive changes and marked cartilage narrowing of wrist, intercarpal, metacarpophalangeal, and proximal interphalangeal joints. The joints involved are typical for rheumatoid arthritis. Alignment abnormalities with ulnar deviation of the metacarpals and osteoporosis are also typical. (B) Coronal short time inversion recovery (STIR) image of the wrist in a different patient showing multiple osseous erosions and synovial thickening, characteristic findings of rheumatoid arthritis. (C) T1 weighted coronal image showing more extensive erosions (*arrows*) with areas of synovial thickening. (D) Axial postcontrast fat-saturated image depicting tenosynovitis, with fluid distention of the tendon sheaths (*arrow*).





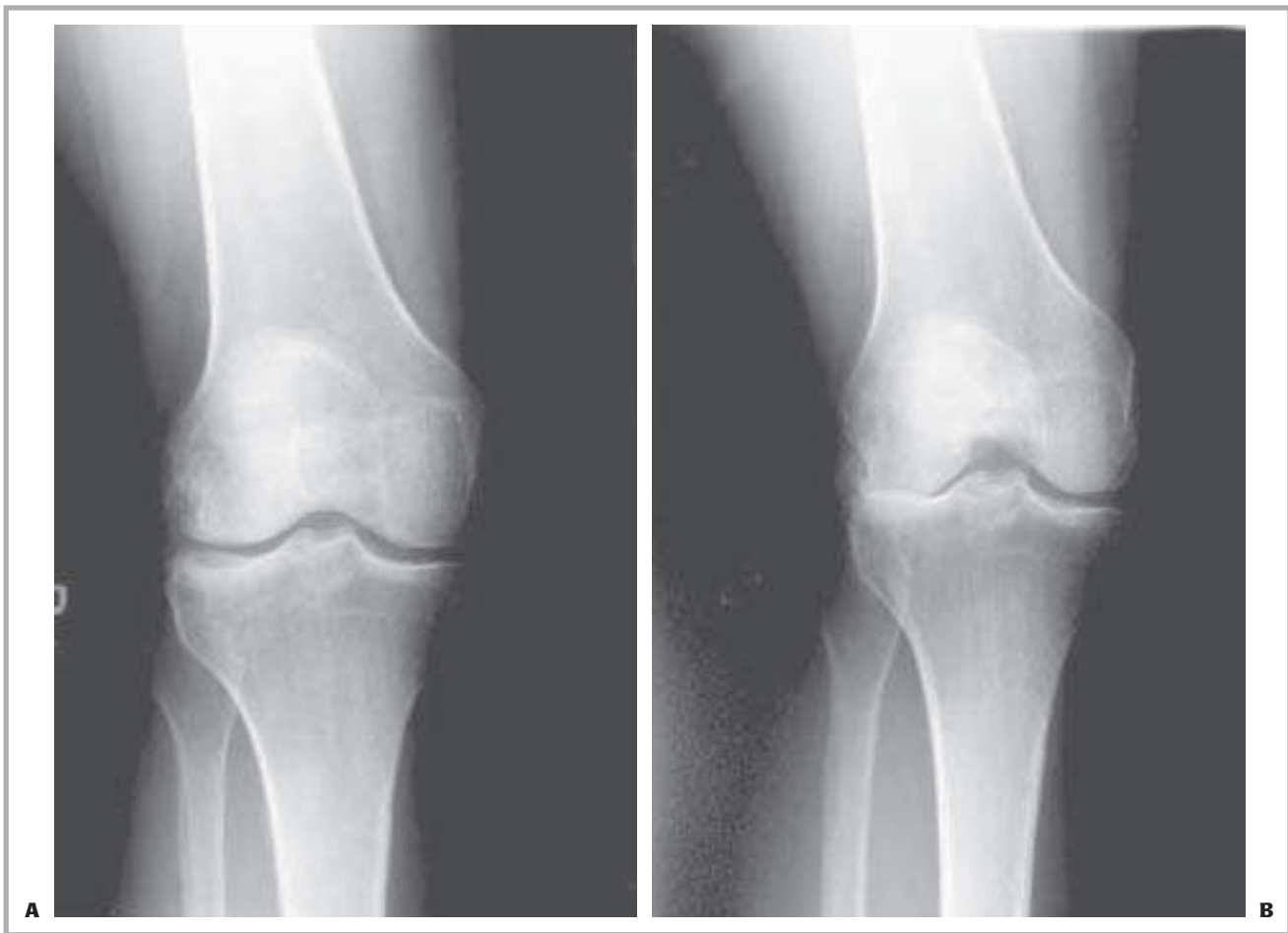
**FIGURE 2D-3**

A 57-year-old woman with systemic lupus erythematosus (SLE) shows striking alignment abnormalities without erosions as well as periarticular osteoporosis. Similar changes are seen in the arthropathy associated with rheumatic fever (Jaccoud's arthropathy). The cartilage destruction and synovial proliferation of rheumatoid arthritis is lacking. Early in the disorder, the alignment abnormalities can be corrected by passive positioning.



**FIGURE 2D-4**

(A) An 80-year-old woman with weakness and pain in the right shoulder. Radiograph shows superior subluxation of the humeral head and markedly decreased space between humeral head and acromion. (B) Oblique-coronal STIR MRI image shows similar decreased distance between the acromion and humeral head, as well as a complete rotator cuff tendon tear. (C) Sagittal oblique T1 weighted image demonstrating a significant degree of atrophy of the supraspinatus, infraspinatus, and subscapularis muscles. MRI findings could have been predicted from the plain radiograph and the clinical history. However, in this case the MRI provides an accurate estimation of the size of the rotator cuff tear, as well as commonly associated findings such as the status of the long head of the biceps tendon and articular cartilage. These soft tissue abnormalities cannot be assessed by plain radiography.

**FIGURE 2D-5**

(A, B) Standing anteroposterior (A) and standing flexed posteroanterior (B) views of the right knee. In (A), no significant narrowing of the joint is identified although osteophytes and subchondral sclerosis, indicative of osteoarthritis, are evident. In (B), however, the standing flexed view demonstrates complete articular cartilage loss in the lateral compartment.

## COMPUTED TOMOGRAPHY

Compared with radiography, CT offers superior contrast resolution, but spatial resolution of CT remains inferior. CT is especially useful in specific locations difficult to evaluate by radiography, such as the sacrum. Although relatively expensive, CT is less costly than MRI. With the advent of multidetector technology capable of producing CT datasets with isotropic resolution, the spatial resolution of CT is comparable or superior to that of MRI, but its contrast resolution is inferior. Consequently, CT is not as sensitive as MRI for defining bone marrow or soft tissue abnormalities.

Computed tomography is an excellent technique for evaluating degenerative disc disease of the spine and possible disc herniations in older patients, in whom radiation dose is less critical than in young patients. CT

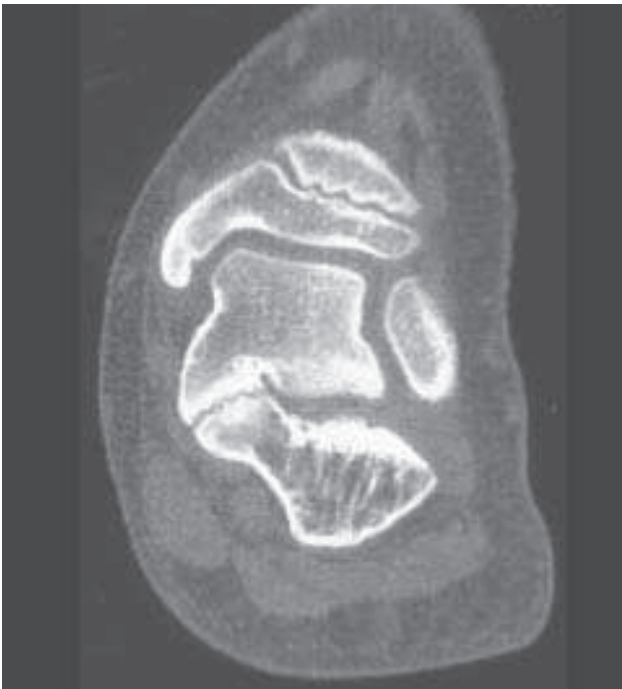myelography and CT with intravenous contrast enhancement are used to evaluate disc disease and other spinal processes. In general, MRI is preferred over CT for investigating disc disease (following plain radiography). For cases in which MRI is contraindicated, CT is an acceptable alternative and may be useful in circumstances where additional information about osteophytes is important. Elsewhere in the musculoskeletal system, CT is useful for evaluating structures in areas of complex anatomy where overlying structures obscure the view on conventional radiographs. Examples include tarsal coalitions not visible on plain radiographs (Figure 2D-6) (1); sacroiliitis, especially that of infectious origin (Figure 2D-7); and articular collapse of the femoral head following osteonecrosis, indicating the need for joint replacement rather than a core procedure. The sternoclavicular joint, which is notoriously difficult to

see on conventional radiography, is quite visible with CT.

The radiation dose from CT is relatively high compared with a single plain radiograph of the same region, but the radiation doses between these imaging techniques are comparable when several conventional radiographic views of the same area are required.

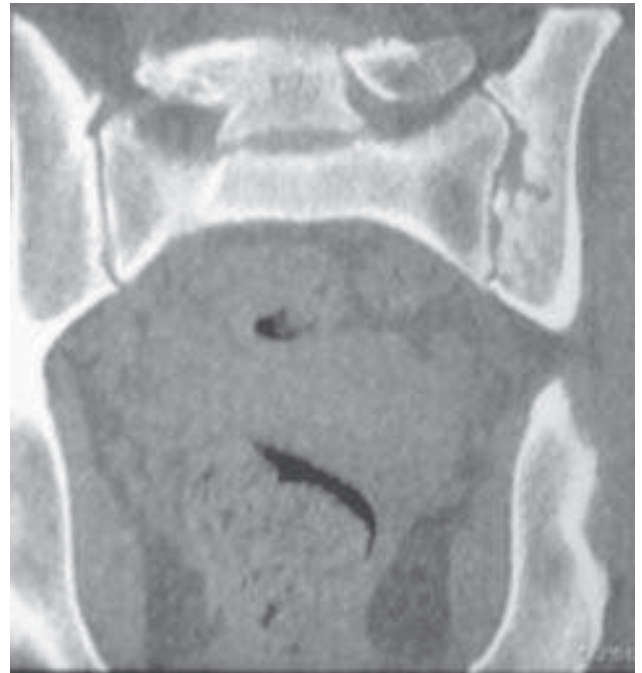If the correct initial data are obtained by appropriately adjusting the thickness of the collimation used and the thickness of the reconstructed slice width, images can be reconstructed satisfactorily in any plane, especially with the advent of advanced multidetector technology capable of isotropic resolution datasets. In addition to multiplanar reconstructions, three-dimensional images can be obtained, which may aid in evaluating abnormalities of the pelvis and other areas of complex anatomy. Using multidetector technology, including multiplanar reformatting, better images of joints affected by respiratory motion, such as the shoulder, can be acquired rapidly during a single breath, minimizing motion artifact.

High resolution (thin cut) CT of the lung may reveal details of disease not seen on thicker CT slices of the thorax. Thin cut CT scans have the additional advantage of not requiring intravenous contrast—often a concern in patients with rheumatic disease who have tenuous renal status. The interstitial lung disease that



**FIGURE 2D-6**

A 50-year-old woman with suspected tarsal coalition. CT scan shows the non-osseous talocalcaneal coalition between the sustentaculum of the calcaneus and the talus above.



**FIGURE 2D-7**

Woman with left hip and back pain. Plain radiographs demonstrated no abnormalities. CT scan shows marked erosion and widening of the left sacroiliac joint, consistent with sacroiliitis. Note relative osteopenia on the adjacent sacral side, indicating hyperemia.

occurs in many patients with a variety of rheumatic conditions (systemic sclerosis, rheumatoid arthritis, inflammatory myopathy, microscopic polyangiitis) is characterized well by high resolution CT. The demonstration of “ground glass” infiltrates connotes an active process that may respond to treatment, but unfortunately this finding does not distinguish between infection, inflammation, and other conditions (2).

Multidetector spiral CT is now used increasingly as a means of excluding pulmonary emboli, a complication to which many patients with rheumatic disorders (systemic lupus erythematosus, primary antiphospholipid antibody syndrome, Wegener’s granulomatosis) are susceptible. For pulmonary thromboembolism detection, the chest is scanned rapidly following a bolus intravenous injection of contrast medium, timed so that the pulmonary arteries are opacified to optimal effect.

## MAGNETIC RESONANCE IMAGING

Because of its ability to image soft tissue structures not visible on conventional radiographs, MRI has brought significant advances to musculoskeletal imaging. The

technique derives structural information from the density of protons in tissue and the relationship of these protons to their immediate surroundings.

Magnetic resonance imaging involves changing the strength and timing of magnetic field gradients, as well as altering radiofrequency pulses and sampling the emitted energy. By altering these factors appropriately, varying amounts of T1 and T2 weighting are imparted to the images. T1 reflects the time constant for spins to align themselves with the main magnetic field of the equipment and T2 reflects the time constant for loss of coherence among spins, resulting in decay of the component of magnetization perpendicular to the main magnetic field. These relaxation times are different in different tissues, permitting optimal imaging of different tissues by selection of an appropriate mix of T1 and T2 weighting.

As a result, MRI highlights different types of tissue and metabolic states. Altering these parameters can produce radically different images of the same anatomic site. CT images, which basically map the density of tissues in a manner similar to conventional radiographs, are intuitively easier to grasp than are MR images.

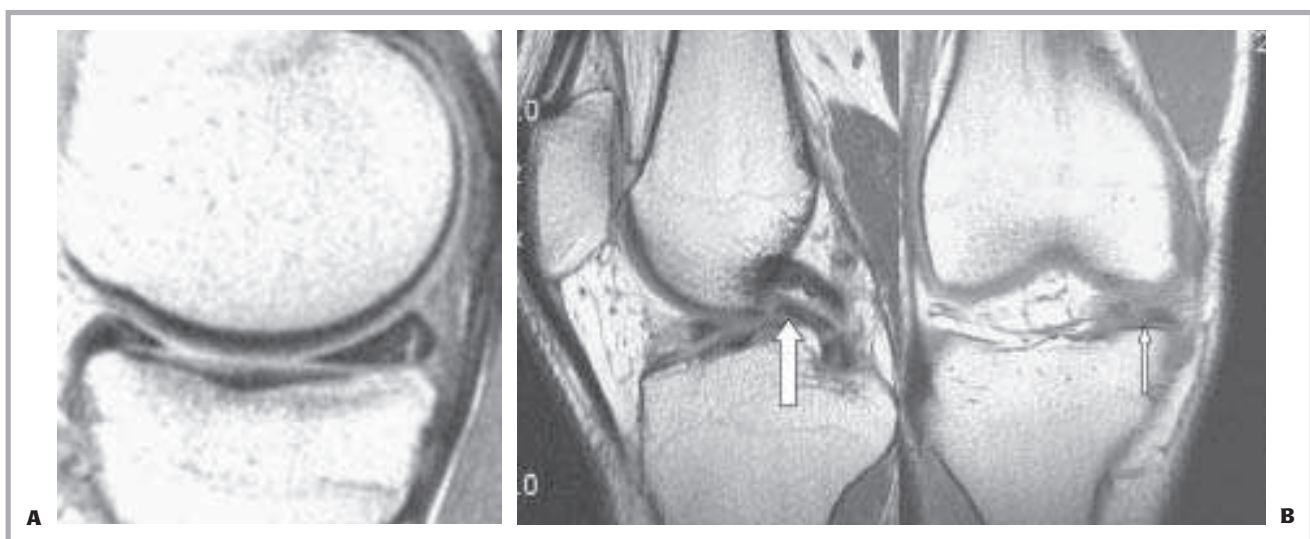
Magnetic resonance imaging is more expensive than most other imaging approaches, largely because of the cost of equipment and the time required to perform the studies. In the future, more attention will probably be given to tailored, limited imaging sequences, which potentially could lower the cost. Newer, faster imaging sequences continue to be developed, which may reduce the time and cost of MRI, as well as provide dynamic studies of joint motion.

Magnetic resonance imaging is free of the hazards of ionizing radiation, a major advantage in examining central portions of the body. The technique does pose some unique potential hazards, however. For example, the strong magnetic field can move metal objects such as surgically implanted vascular clips and foreign metal in the eyes, cause pacemaker malfunction, heat metal objects, and draw metal objects into the magnet. Metallic objects in the vicinity of the magnetic field can also compromise the quality of MRI images. Because of these risks and the adverse effect on imaging quality, operators must screen patients and visitors carefully. Patients suffering from claustrophobia may be unable to tolerate the procedure, which is performed with the patient positioned in a hollow tube. More open configurations for the magnet can circumvent this problem, but the quality of images produced by these devices varies. MRI  $\bar{c}$  gadolinium is contraindicated in patients with significant renal dysfunction, because of the risk of inducing nephrogenic systemic fibrosis (3). Finally, because MRI instruments can be noisy, hearing protection should be provided for the patient.

Spatial resolution using the latest MRI equipment is similar to spiral CT, but contrast resolution in soft tissues as well as bone marrow is superior among imaging modalities. Intra-articular soft tissue structures, such as the menisci and cruciate ligaments of the knee, are demonstrated clearly by MRI (Figure 2D-8). In fact, tiny ligamentous structures in the wrist or ankle can be assessed quite readily (4). The synovium can be imaged, especially using intravenous gadolinium. Joint effusions, popliteal cysts, ganglion cysts, meniscal cysts, and bursi-

#### FIGURE 2D-8

(A) Sagittal proton density images of the knee, depicting vertical tear of the posterior horn of the medial meniscus. (B) Sagittal proton density images of the knee. Bucket-handle tear of the medial meniscus, with "double Posterior Cruciate Ligament sign."



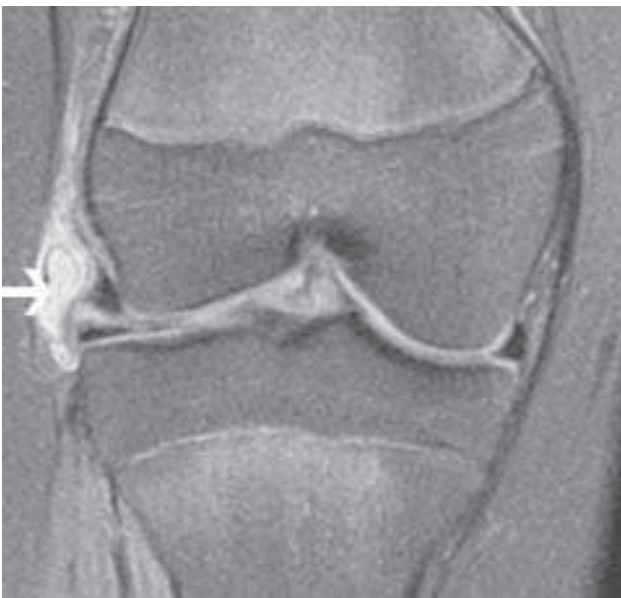

tis can be imaged clearly (Figure 2D-9), and the integrity of tendons assessed accurately as well (5). One limitation of MRI is in the detection of calcifications, which present as signal voids and are therefore not as well seen by MRI as by radiographic images. For example, chondrocalcinosis, important to the diagnosis of calcium pyrophosphate dehydrate deposition disease (CPPD), is demonstrated more reliably by plain radiography (Figure 2D-10). Otherwise, MRI remains the modality of choice for evaluating potential internal joint derangements.

Magnetic resonance imaging has specific utility in the assessment of:

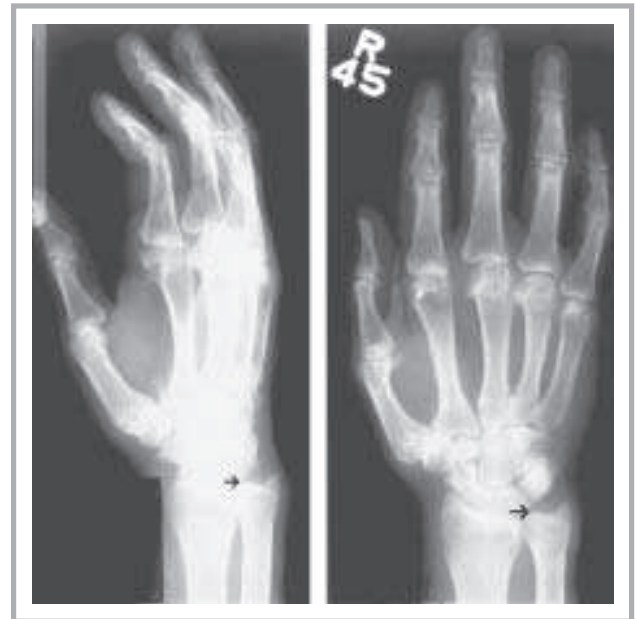- **Imaging Cartilage.** MRI has a negative predictive value close to 100% for the presence of meniscal tears in the knee. MRI is also a sensitive method for diagnosing labral tears of the shoulder and triangular fibrocartilage tears in the wrist.

Alterations in articular hyaline cartilage are visible on MRI. Although direct observation with arthroscopy is more sensitive to small superficial changes, refinements are being made that improve the ability of MRI to detect small articular cartilage defects (6). With recent improvements in therapy for cartilage defects, MRI provides a useful noninvasive method for quantifying cartilage loss as well as evaluating the success of surgical repair. In addition, MRI is the study of choice for evaluating osteochondritis dissecans when information is needed about whether the osteochondral fragment is loose or detached.



**FIGURE 2D-9**

Adolescent with knee pain. Coronal proton density fat-saturated image shows horizontal cleavage tear of the lateral meniscus, with associated parameniscal cyst (arrow).



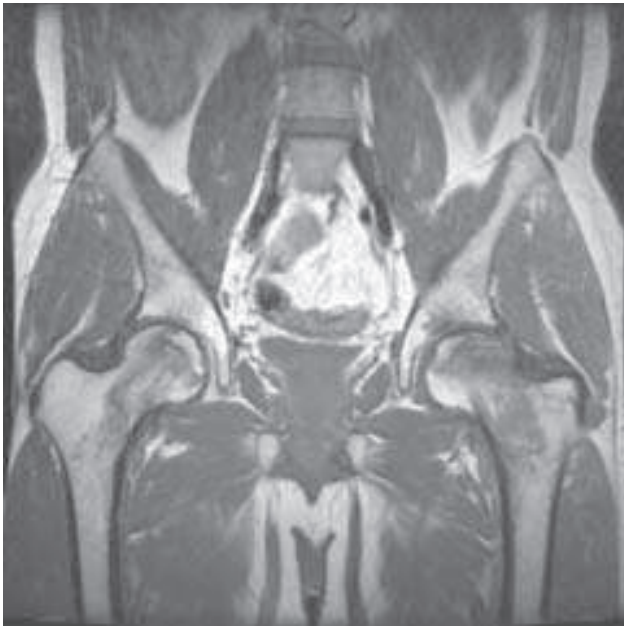
**FIGURE 2D-10**

Chondrocalcinosis in the hand: 58-year-old man with chondrocalcinosis in triangular fibrocartilage and lunotriquetral ligaments (arrows). Note MCP joint degenerative changes, a typical location for CPPD arthropathy. First carpometacarpal (CMC) joint also shows moderate degenerative change.

Recent studies have suggested that MRI may have a role in assessing responses to therapy in arthritis. For example, in rheumatoid arthritis, MRI can quantify the volume of enhancing inflammatory tissue (7). In ankylosing spondylitis, MRI may be used to assess changes over time in spinal inflammation (8). MRI has been established as the most sensitive modality for the detection of bony erosions (Figure 2D-11) (9), although its specificity for early erosive changes has been reported to be low. Healthy subjects can occasionally demonstrate imaging findings suggestive of mild synovitis or erosions, indistinguishable from early rheumatoid arthritis (10). Finally, as bone marrow edema and synovitis can precede frank erosions, MRI may have a predictive role, and thus affect patient management early in the disease course (11).

- **Detecting Bony Abnormalities.** MRI is extremely sensitive to subtle bony abnormalities. In fact, microfractures due to trauma or stress—often referred to as “bone bruises”—were essentially unknown before MRI. Now, recognizing their presence is quite important. The pattern of bone bruises is also closely related to ligamentous injuries (12). Similarly, much of the pain accompanying some acute meniscal tears may be caused by associated bone marrow edema. When the edema subsides, the pain disappears, despite the persistent meniscal tear. This finding





**FIGURE 2D-11**

MRI images of a patient treated with corticosteroids. T1 weighted image of hips demonstrates characteristic serpentine foci of low signal intensity within the femoral heads bilaterally, consistent with osteonecrosis.

could have important implications for therapy. One should possibly wait for the edema to resolve before attempting surgical intervention to repair or remove the meniscus. In some cases intervention might be unnecessary. MRI studies of the knee in older people often reveal asymptomatic meniscal tears. These individuals may have had pain at the time of the tear which resolved with the edema and did not cause them long-term disability.

- **Diagnosing Osteonecrosis.** MRI is the study of choice for diagnosing osteonecrosis (Figure 2D-11). Early in the course of disease, plain radiographs show no abnormalities.
- **Evaluating Musculoskeletal Neoplasms.** MRI is also the best method for evaluating the extent of a musculoskeletal neoplasm. Plain radiographs are still the mainstay for detecting bone neoplasms.
- **Identifying Bone Infections.** MRI is highly sensitive to the presence of bone infection because of alterations in the marrow signal. Osteomyelitis cannot be detected on radiography until approximately 30% to 40% bone destruction has occurred. Thus, MRI is the study of choice for the early detection of osteomyelitis (13). Small studies have shown variable results for MRI in differentiating osteomyelitis and neuropathic arthropathy, which is very difficult with other imaging techniques.

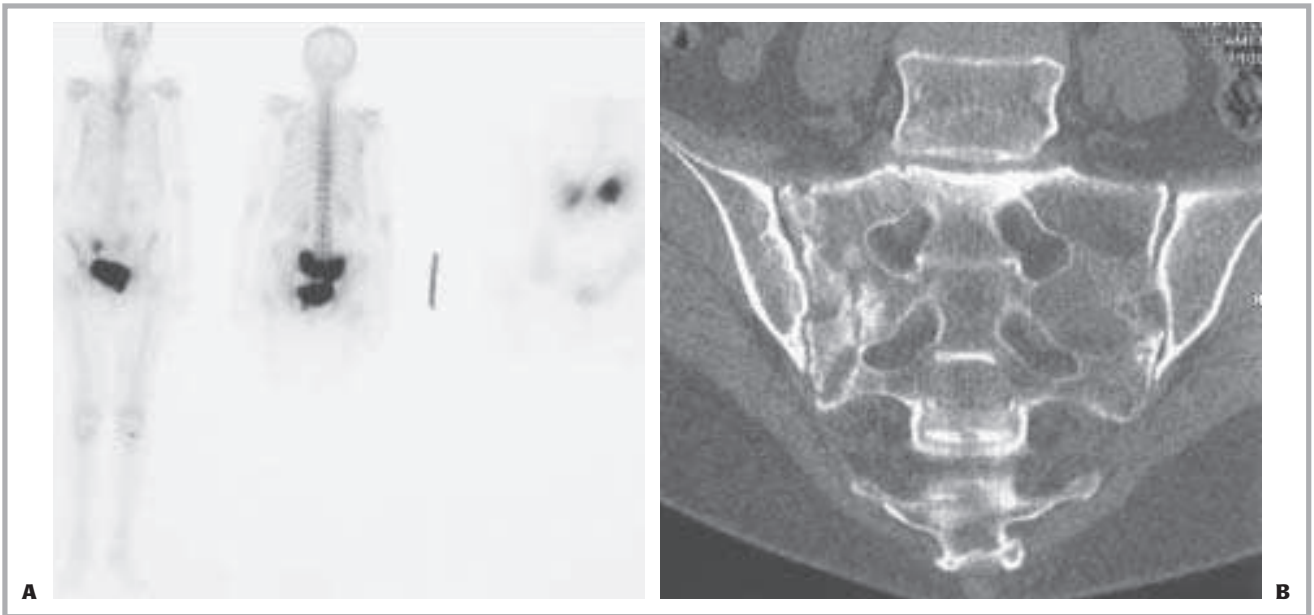
- **Diagnosing Disc Herniation.** Following plain radiography, MRI is an excellent study of the spine and its contents in cases of suspected disc herniation, particularly in young patients, because it does not employ ionizing radiation.
- **Localizing Muscle Abnormalities, Including Inflammation-Associated Edema in Inflammatory Muscle Disease.** MRI is indicated in the assessment of muscle abnormalities for detection of potential tears and contusions. The activity of different muscles during joint motion can also be studied by noting signal changes that occur with muscle activity. In inflammatory myopathies (polymyositis, dermatomyositis, inclusion body myositis), MRI demonstrates characteristic (albeit not diagnostic) edema, and may be useful in identifying sites to biopsy and following disease activity.

## SCINTIGRAPHIC TECHNIQUES

Scintigraphy following intravenous administration of agents such as  $^{99m}\text{Tc}$  methylene diphosphonate ( $^{99m}\text{Tc}$  MDP) for bone scans,  $^{99m}\text{Tc}$  sulphur colloid for bone marrow scans,  $^{67}\text{Ga}$  citrate ( $^{67}\text{Ga}$  citrate), and leukocytes labeled with  $^{111}\text{In}$  [ $^{111}\text{In}$ -labeled white blood cells (WBCs)] are useful for evaluating a variety of musculoskeletal disorders (Figure 2D-12). These studies, similar in cost to CT, deliver a radiation dose similar to a CT scan of the abdomen. Scintigraphy is quite sensitive for detecting many disease processes, and has the advantage of imaging the entire body at once. The technique is nonspecific, however, because a number of processes may cause radionuclide accumulation. When areas of increased uptake are detected, additional studies such as radiography are often necessary to define the type of abnormality further. In clinical situations where the presence of skeletal disease is uncertain, a bone scan can be useful in excluding disease.

### Localization of Scintigraphic Imaging Agents

$^{99m}\text{Tc}$  Technetium methylene diphosphonate, the most commonly used radionuclide, accumulates in areas of bone formation, calcium deposition, and high blood flow.  $^{99m}\text{Tc}$  sulphur colloid localizes in the reticuloendothelial system (liver, spleen, and bone marrow).  $^{67}\text{Ga}$  citrate accumulates in inflammatory and certain neoplastic processes, and  $^{111}\text{In}$ -labeled WBCs localize in inflammatory sites, especially acute inflammatory processes.

**FIGURE 2D-12**

(A) An 82-year-old woman with a history of breast cancer and recent onset of lower back pain. Metastases were suspected.  $^{99m}\text{Tc}$  MDP bone scan shows increased uptake in the sacrum and right pubic ramus, typical of insufficiency fractures rather than metastatic cancer. (B) Computed tomography scan in the same 82-year-old woman. This test demonstrates the linear nature of the healing fracture in the sacrum, adjacent to the right sacroiliac joint, lending specificity to the diagnosis suggested by the radionuclide scan.

## Using Radionuclide Imaging to Diagnose Osteomyelitis

The  $^{99m}\text{Tc}$  MDP triple-phase bone scan is commonly used for early detection of osteomyelitis. Images are obtained in the early vascular phase (during bolus injection of the radionuclide), intermediate blood pool phase (5 minutes postinjection), and late bone phase (3 hours postinjection). A fourth phase (24 hours postinjection) can be added to accentuate areas of increased bone uptake, during which time soft tissue background is decreased, although delayed imaging is not widely used because of its inconvenience. If necessary, the specificity of scanning can be increased by also using  $^{67}\text{Ga}$  gallium citrate or  $^{111}\text{In}$ -labeled WBCs. The  $^{111}\text{In}$ -labeled WBC scan is especially useful when osteomyelitis is suspected to be superimposed on a healing fracture or surgical incision because uptake of  $^{99m}\text{Tc}$  MDP is increased at these sites even in the absence of infections.  $^{111}\text{In}$ -labeled WBC scans may also be useful in diagnosing osteomyelitis of the foot in people with diabetes. In suspected osteomyelitis of the hematopoietic bone marrow, the combination of  $^{99m}\text{Tc}$  MDP and  $^{111}\text{In}$ -labeled WBC appears to be an effective diagnostic technique. Spatial localization of bone scans can be improved with single-photon emission computed tomography (SPECT), and radiographs of scan-positive areas can be used to increase specificity.

## Other Uses of Radionuclide Imaging

Bone scans are a reasonable alternative for early detection of osteonecrosis if MRI is not available. Bone scans can also detect stress injuries such as shin splints, tendon avulsions, insufficiency fractures, and stress fractures, which sometimes mimic arthritis symptoms (Figure 2D-12).

## ULTRASOUND

Ultrasound provides unique information by creating images based on the location of acoustic interfaces in tissue. It is relatively inexpensive, widely available, and free of the hazards of ionizing radiation. Spatial resolution is similar to CT and MRI, but this depends on the transducer. However, resolution is limited by the depth of tissue being studied; resolution is much higher for superficial structures.

One limitation of ultrasound is dependence on the operator. It is not always possible for one investigator to reproduce the results of another. Furthermore, because ultrasound has no cross-sectional orientation, it may be difficult for individuals who were not actually present during the study to interpret the images later.

In some centers, ultrasound has proved accurate in detecting rotator cuff tears. It is also excellent for

assessing fluid collections, such as joint effusions, popliteal cysts, and ganglion cysts, and can therefore be used to guide aspiration of fluid. Superficially located tendons, such as the Achilles tendon and patellar tendon, can be studied for tears.

Ultrasound is excellent for differentiating thrombophlebitis from pseudothrombophlebitis. With real-time compression ultrasonography, venous thrombosis and popliteal cysts can be identified.

Ultrasound, similar to MRI, has been shown to be much more sensitive than radiography in detection of erosions in rheumatoid arthritis (14). With amplitude color Doppler (ACD), it can demonstrate synovial hyperemia in active disease. The technique requires a skilled operator and is more effective in the examination of the metacarpophalangeal (MCP) and interphalangeal (IP) joints than the intercarpal joints, but is relatively inexpensive and convenient. It avoids the potentially uncomfortable positioning that may be necessary with MRI.

Finally, although ultrasound has been reported to be useful in the diagnosis of temporal arthritis, there is an absence of blinded studies confirming its utility for this purpose.

## ARTHROGRAPHY

Arthrography involves injecting a contrast agent into the joint followed by radiography. In conventional arthrography, the joint cavity is filled with an iodine-

containing contrast medium and sometimes air. The cost is less than that of CT or MRI, and the procedure can be performed wherever fluoroscopy is available. The possibility of introducing bacteria into a joint or encountering reactions to the local anesthetic or contrast medium must be considered, but these complications are very rare.

One of the major reasons for developing arthrography was to examine structures within the joint, such as the menisci of the knee, which were not visible on conventional radiographs. Now these structures can be imaged noninvasively by MRI. However, certain important roles remain for arthrography.

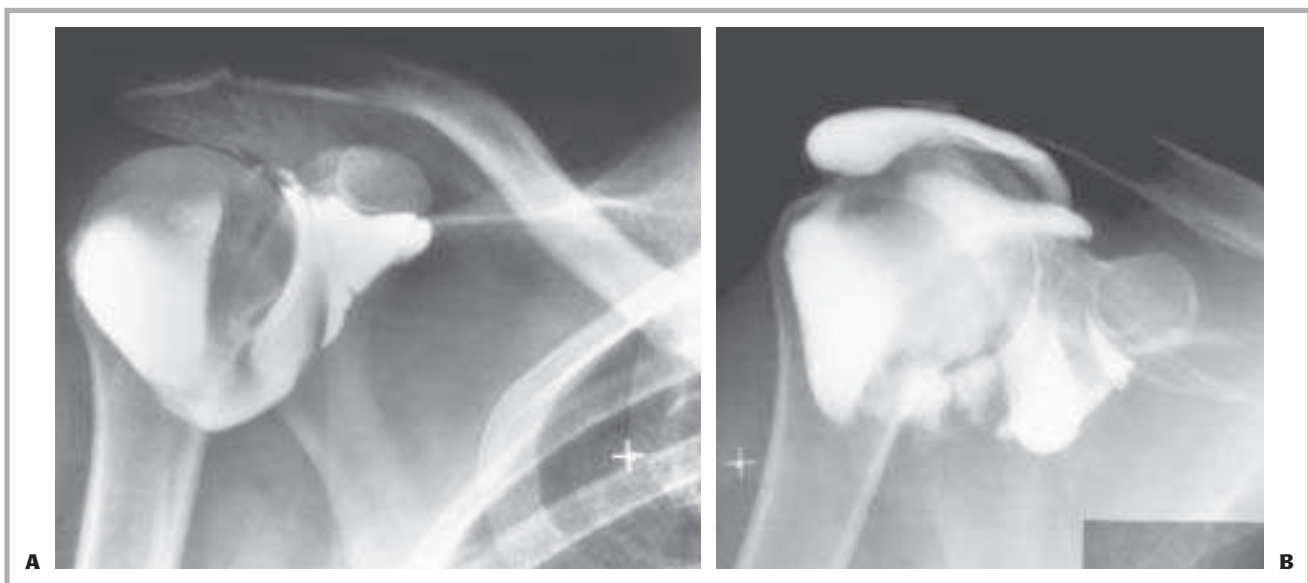
Conventional arthrography, using iodine-containing contrast medium either alone or combined with air, accurately detects full-thickness rotator cuff tears (Figure 2D-13). CT scanning can be added to the air-contrast arthrogram (CT arthrography), providing an excellent study of the glenoid labrum that can be an alternative to MRI in selected patients (15).

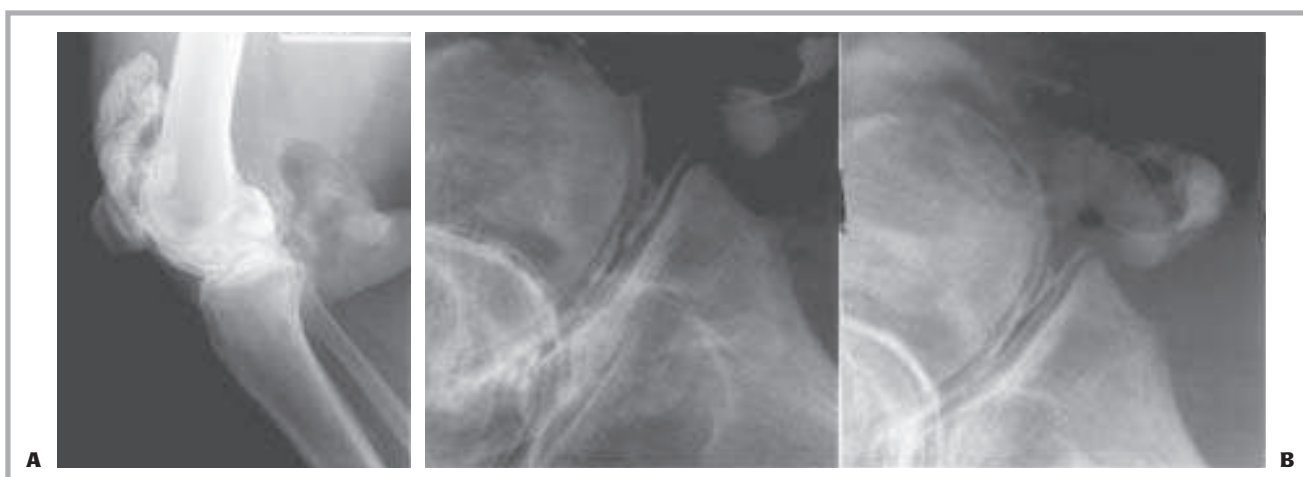
Knee arthrography can confirm the diagnosis of a popliteal cyst, and permits injection of corticosteroids at the same time. It is an alternative for evaluating the menisci in patients who are claustrophobic or whose size precludes MRI examination (Figure 2D-14).

Wrist arthrography is excellent for evaluating the integrity of the triangular fibrocartilage, ligaments between the scaphoid and lunate, and ligaments between the lunate and triquetrum (16). Some clinicians prefer arthrography to MRI in this situation.

### FIGURE 2D-13

(A) Single contrast arthrogram of a normal shoulder. (B) Single contrast shoulder arthrogram of a 66-year-old man with a painful shoulder and history of injury in distant past. Contrast media fills not only the shoulder joint [as in Figure 2D-11(A)] but has filled the subdeltoid-subacromial bursa superiorly, a finding diagnostic of full-thickness rotator cuff tear.



**FIGURE 2D-14**

(A, B) A 40-year-old woman, too large to fit in the MRI scanner, was suspected of having a popliteal cyst. Double contrast arthrogram demonstrated popliteal cyst and also a torn medial meniscus. Ultrasonography would have been an appropriate alternative approach to making this diagnosis.

Magnetic resonance arthrography is performed by distending a joint with a dilute solution of a gadolinium-containing contrast medium. This technique, not widely studied, probably increases the diagnostic accuracy of glenoid and acetabular labral tears, as well as rotator cuff tears (17).

## BONE DENSITOMETRY

Bone densitometry is used primarily for evaluating osteoporosis. Two precise, accurate, and widely available techniques are dual-energy x-ray absorptiometry (DXA) and quantitative computed tomography (QCT) (18).

Dual-energy x-ray absorptiometry scans with a narrow x-ray beam that alternates energy (kilovoltage peak; KVP). A sensitive receptor detects the fraction of the x-ray beam that traverses the body at each point along the scan path. Because the absorption characteristics of bone and soft tissue vary at different x-ray energies, the amount of radiation absorbed by bone can be calculated. From this, the amount of bone in the path of the x-ray beam at any point along the scan is determined.

Dual-energy x-ray absorptiometry is relatively inexpensive and delivers very little radiation to the patient. It is thus a good choice for studies that must be repeated. Any part of the body can be studied. Standard values

are available for lumbar spine and proximal femur, which are the most widely studied.

Quantitative computed tomography scans several lumbar vertebrae while simultaneously scanning a phantom containing different concentrations of bone-equivalent material. A standard curve is constructed from the concentration values versus CT attenuation, and then the bone density at any location scanned is determined from the standard curve. The cost of this study is moderate and the radiation dose fairly low, although not as low as that for DXA. One purported advantage of this technique is that trabecular bone in the middle of the vertebrae can be evaluated because overlying cortical bone and posterior elements of the vertebrae are not measured. Trabecular bone, which has tremendous surface area, is more rapidly affected during bone loss than is cortical bone.

## ANGIOGRAPHY

Angiography is useful in the primary diagnosis of rheumatologic disorders with vascular components. In polyarteritis nodosa, for example, demonstration of multiple small aneurysms in medium-sized arteries may be diagnostic. Similarly, in Takayasu's arteritis, the long, smooth tapering of involved vessels—most often the subclavian arteries—is highly characteristic. Aortography with central aortic pressure measurement is also



important in patients with Takayasu's disease, whose blood pressures in the arms and sometimes even the legs are not accurate because of proximal arterial narrowing. In Buerger's disease, angiography reveals "corkscrew" collaterals at the levels of the hands and wrists.

## IMAGE-GUIDED ASPIRATION AND INJECTIONS

Examination of joint fluid often plays an important part in the diagnosis of arthritic conditions such as septic arthritis, gout, and pseudogout. In most cases, the rheumatologist has no difficulty in obtaining fluid using external landmarks for needle placement. In more difficult cases, aspiration using imaging guidance may prove useful. The source of the specimen can be documented by contrast injection and radiography.

Using imaging guidance to be certain of needle tip position, injection of specific joints with local anesthetic can prove whether or not the joint is responsible for the patient's pain. The injection of glucocorticosteroids for longer term relief can be directed in a similar fashion for greater precision in administration.

## IMAGING DECISIONS

Almost all imaging should begin with plain radiography, which is frequently all that is required. If additional diagnostic information is required to make clinical decisions, MRI is frequently the second imaging study. In many cases, MRI findings must be correlated with plain films because MRI does not easily demonstrate soft tissue calcifications or subtle cortical abnormalities of bone.

Recent MRI studies show that many individuals have anatomic abnormalities that are unrelated to symptoms (19). Therefore, imaging findings must be correlated with the clinical presentation. Imaging studies should not be obtained unless they have the potential to answer clinically significant questions. In the absence of clear clinical questions, imaging studies may raise more questions than they answer.

Finally, it is critically important for the clinician to work closely with the radiologist to decide exactly what information is needed from an imaging study, and then to select the technique that will supply that information. MRI provides such a wealth of information about so many structures that an exhaustive MRI study may be appropriate in a very puzzling joint condition. In other cases, a tailored, abbreviated MRI or a simpler imaging procedure may provide the specific diagnostic information in less time for less money.

## REFERENCES

1. Wechsler RJ, Karasick D, Schweitzer. Computed tomography of talocalcaneal coalition: imaging techniques. *Skeletal Radiol* 1992;21:353-359.
2. Lee JS, June-GI I, Ahn JM, Kim YM, Han MC. Fibrosing alveolitis: prognostic implication of ground glass attenuation of high-resolution CT. *Radiology* 1992;184:451-454.
3. Kuo PH, Kanal E, Abu-Alfa AK, Cowper SE. Gadolinium-based MR contrast agents and nephrogenic systemic fibrosis. *Radiology* 2007;242:647-649.
4. Schweitzer ME, Brahme SK, Hodler J, et al. Chronic wrist pain: spin-echo and short tau inversion recovery MR imaging and conventional and MR arthrography. *Radiology* 1992;182:205-211.
5. Schweitzer ME, Caccese R, Karasick D, Wapner KL, Mitchell DG. Posterior tibial tendon tears: utility of secondary signs for MR imaging diagnosis. *Radiology* 1993;188:655-659.
6. McCauley TR, Disler DG. MR imaging of articular cartilage. *Radiology* 1998;209:629-640.
7. Argyropoulou MI, Glatzouni A, Voulgari PV, et al. Magnetic resonance imaging quantification of hand synovitis in patients with rheumatoid arthritis treated with infliximab. *Joint Bone Spine* 2005;72:557-561.
8. Sieper J, Baraliakos X, Listing J, et al. Persistent reduction of spinal inflammation as assessed by magnetic resonance imaging in patients with ankylosing spondylitis after 2 yrs of treatment with the anti-tumour necrosis factor agent infliximab. *Rheumatology* 2005;44:1525-1530.
9. Hoving JL, Buchbinder R, Hall S, et al. A comparison of magnetic resonance imaging, sonography, and radiography of the hand in patients with early rheumatoid arthritis. *J Rheumatol* 2004;31:663-675.
10. Ejlberg B, Narvestad E, Rostrup E, et al. Magnetic resonance imaging of wrist and finger joints in healthy subjects occasionally shows changes resembling erosions and synovitis as seen in rheumatoid arthritis. *Arthritis Rheum* 2004;50:1097-1106.
11. Benton N, Stewart N, Crabbe J, et al. MRI of the wrist in early rheumatoid arthritis can be used to predict functional outcome at 6 years. *Ann Rheum Dis* 2004;63:555-561.
12. Mair SD, Schlegel TF, Gill TJ, Hawkins RJ, Steadman JR. Incidence and location of bone bruises after acute posterior cruciate ligament injury. *Am J Sports Med* 2004;32:1681-1687.
13. Aloui N, Nessib N, Jalel C. Acute osteomyelitis in children: early MRI diagnosis. *J Radiol* 2004;85:403-408.
14. Wakefield RJ, Gibbon WW, Conaghan PG, et al. The value of sonography in the detection of bone erosions in patients with rheumatoid arthritis: a comparison with conventional radiography. *Arthritis Rheum* 2000;43:2762-2770.
15. Stiles RG, Otte MT. Imaging of the shoulder. *Radiology* 1993;188:603-613.
16. Metz VM, Mann FA, Gilula LA. Three-compartment wrist arthrography: correlation of pain site with location of uni- and bidirectional communications. *AJR Am J Roentgenol* 1993;160:819-822.



17. Palmer WE, Brown JH, Rosenthal DI. Labral-ligamentous complex of the shoulder: evaluation with MR arthrography. *Radiology* 1994;190:645–651.
18. Guglielmi G, Grimston SK, Fischer KC, Pacifici R. Osteoporosis: diagnosis with lateral and posteroanterior dual x-ray absorptiometry compared with quantitative CT. *Radiology* 1994;192:845–850.
19. Jensen MC, Brant-Zawadski MN, Obuchowski N, et al. Magnetic resonance imaging of the lumbar spine in people without back pain. *N Engl J Med* 1994;331:69–73.