

01

FUNDAMENTALS
AND PRACTICAL
BASIS

ARTHROCENTESIS

Felipe de Vicente

INTRODUCTION

The purpose of arthrocentesis is to obtain a sample of synovial fluid from a joint. Arthrocentesis and synovial fluid analysis allow for differentiation between the different types of joint disease. In general terms, arthropathies in small animals can be inflammatory (Fig. 1) or noninflammatory (Fig. 2). The former may be infectious, immune-mediated or crystal-induced (e.g. hydroxyapatite) in origin. Immune-mediated arthropathies are in turn classified into erosive and nonerosive.

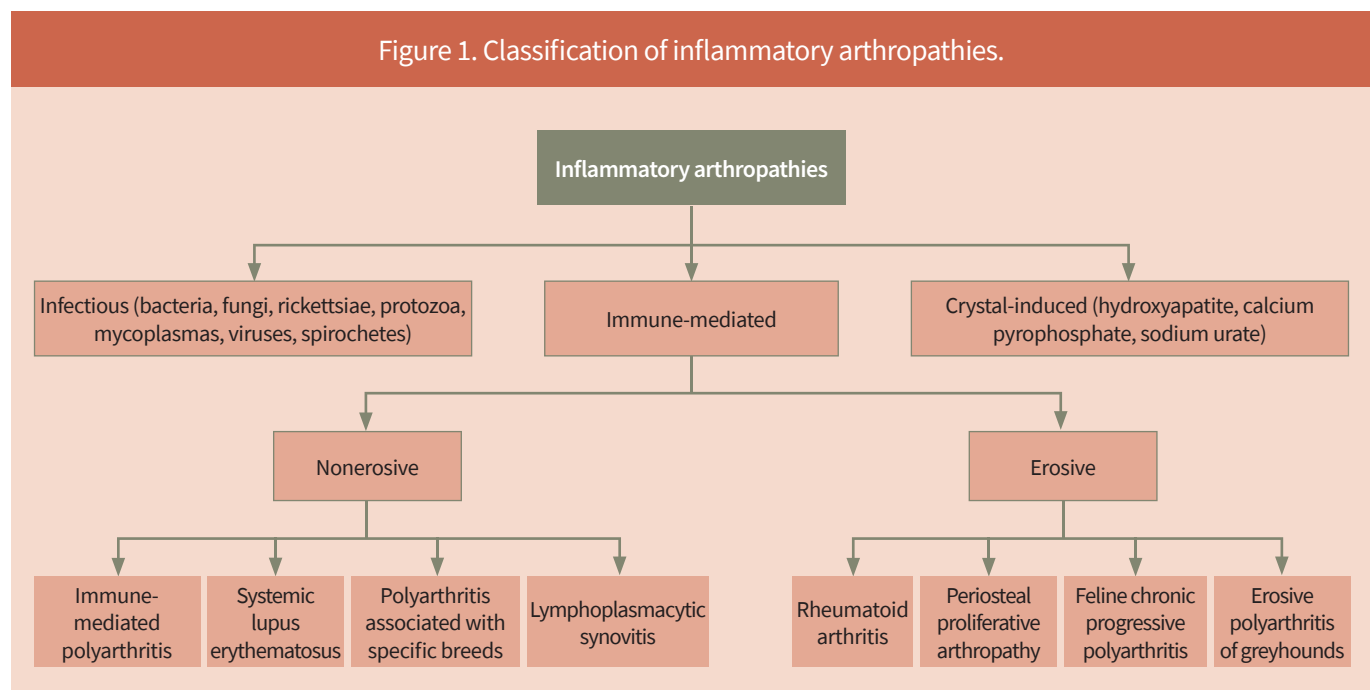
The most common joint diseases in small animals are noninflammatory in nature, and most often are degenerative arthropathies (osteoarthritis) secondary to degenerative joint conditions. It has been estimated that 20 % of adult dogs and more than 60 % of cats suffer from osteoarthritis (Johnston, 1997; Hardie et al., 2002). Other less common types of noninflammatory joint diseases are arthropathies associated with trauma, tumours or coagulopathies.

The most common cause of infectious inflammatory arthropathy is bacterial infection. Other causes of infectious inflammatory joint disease have been described, such as rickettsiae (*Ehrlichia*), protozoa (*Leishmania*), fungi (*Aspergillus*, *Cryptococcus*), mycoplasmas, viruses (feline calicivirus, feline coronavirus) and spirochetes (*Borrelia*), among others.

The most common cause of noninfectious inflammatory arthropathy is immune mediated. In addition to immune-mediated polyarthritis, other causes of nonerosive immune-mediated joint disease include arthropathies associated with certain breeds (e.g. Akita and Shar Pei), osteoarthritis associated with systemic lupus erythematosus and lymphoplasmacytic synovitis.

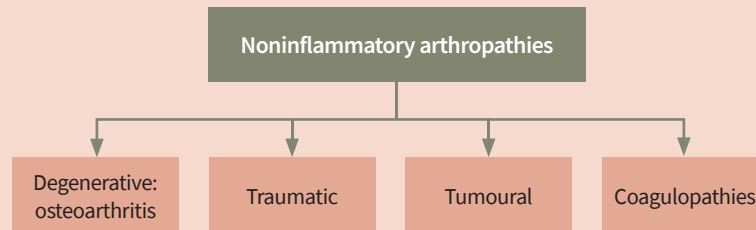
Finally, erosive immune-mediated inflammatory arthropathies include rheumatoid arthritis, erosive polyarthritis of greyhounds, feline chronic progressive polyarthritis and periosteal proliferative arthropathy.

Figure 1. Classification of inflammatory arthropathies.



Adapted from Johnston SA, Tobias KM, *Veterinary Surgery: Small Animal Expert Consult*, 2nd ed. (2018).

Figure 2. Classification of noninflammatory arthropathies.



Adapted from Johnston SA, Tobias KM, *Veterinary Surgery: Small Animal Expert Consult*, 2nd ed. (2018).

INDICATIONS

Arthrocentesis is a technique indicated to evaluate synovial fluid in patients with suspected arthropathy.

Synovial fluid analysis should be interpreted in conjunction with the patient's clinical signs, physical and orthopaedic examination findings and results of imaging of the affected joints.

CLINICAL SIGNS OF THE MOST COMMON ARTHROPATHIES

Clinical signs in animals with arthropathies vary from stiffness when walking to acute or chronic lameness. Lameness can occur with varying degrees of severity and can affect one or more limbs. Depending on the chronicity of the lameness, patients may have muscular atrophy or asymmetry in the affected limb. Some patients with inflammatory joint disease may present with fever (especially those with immune-mediated arthropathies) and nonspecific clinical signs of systemic disease (e.g. malaise, anorexia, enlarged lymph nodes).

Upon orthopaedic examination, it is possible to detect joint effusion in the affected limbs, and patients may show pain or discomfort upon palpation or when moving the joint. Also, when moving the joint throughout its range of motion, crepitus may be felt or the range of motion may be reduced.

It is very common to perform imaging tests on joints suspected of arthropathy. Although advanced diagnostic techniques can be performed (usually a CT scan, and less

frequently an MRI), it is more common to perform orthogonal radiographs of the affected joint. Radiological findings depend on the cause of the arthropathy, and sometimes joints are radiologically normal even with disease. Nonspecific radiological changes, such as of effusion, distension of the joint capsule, osteophytosis, enthesiophytosis, subchondral sclerosis or thickening of periarticular soft tissues, are very frequent. These nonspecific radiographic findings are common in degenerative arthropathies (e.g. secondary to elbow dysplasia or rupture of the cranial cruciate ligament of the stifle). In contrast, in inflammatory arthropathies, changes such as lysis or sclerosis of the subchondral bone can be observed in some infectious conditions, whereas joint collapse with lysis and destruction of the subchondral bone can be observed in erosive inflammatory arthropathies.

TECHNIQUE

Arthrocentesis is performed by puncturing the joint with a hypodermic needle. The anatomical locations for this puncture have already been described for each joint (Clements, 2006; Torres and Duerr, 2020). This technique may cause discomfort and pain to the patient; therefore, sedation or anaesthesia is recommended for the procedure. Sedating the patient also decreases the probability of causing iatrogenic damage to the joint during sampling. Since most patients suspected of having joint disease undergo a diagnostic imaging study, it is common to perform arthrocentesis immediately after the imaging study, under the same sedation or anaesthesia.

The arthrocentesis technique must be performed aseptically, using sterile syringes, needles and gloves.

The patient is positioned in lateral recumbency and the area where the arthrocentesis is to be performed (usually a 5 × 5 cm square) is clipped and aseptically prepared. It is common to note an increase in resistance when passing through the joint capsule and inserting the hypodermic needle into the joint. The size of the hypodermic needle depends on the size of the joint to be tapped and on the size of the patient. Generally speaking, a 20–22-gauge needle is used in medium to large patients, and a 22–25-gauge needle is used in cats and small dogs. Once the joint has been punctured and synovial fluid has been obtained, it is important to cease aspirating with the syringe while leaving the joint to avoid contaminating the sample with peripheral blood.

Although there may be minor variations in the arthrocentesis technique, the current recommendations for each joint are described below.

SHOULDER ARTHROCENTESIS

Arthrocentesis of the shoulder joint can be performed through a lateral or cranial approach. A 22-gauge hypodermic needle 40 mm long is usually used for the procedure, although an 80 mm long needle may be necessary in giant-breed dogs.

Palpating the shoulder joint may be difficult, so anatomical landmarks are used to locate it. To perform lateral

arthrocentesis, the shoulder is held in a neutral position, the acromial process of the scapula is taken as a landmark and the hypodermic needle is inserted immediately distal to it, directing the needle perpendicular to the scapula (Fig. 3).

The other option is to perform the technique via a cranial approach. In this case, the greater tubercle of the humerus is used as an anatomical landmark and the needle is introduced immediately medial to it (and distal to the supraglenoid tubercle of the scapula) in a craniocaudal direction (Fig. 4).

ELBOW ARTHROCENTESIS

Arthrocentesis of the elbow joint is usually performed with a 22-gauge needle, 40 mm in length. This technique is performed with the patient in lateral recumbency, and the sample is taken from the lateral aspect of the elbow. The author usually places the patient's elbow in a slightly flexed position (approximately 15–25 degrees of angulation). The lateral part of the humeral condyle and the olecranon of the ulna are located and used as anatomical landmarks. The hypodermic needle is introduced caudal and medial to the lateral condyle of the humerus, proximal to the olecranon, in a proximodistal direction between the most distal part of the lateral supracondylar crest of the humerus and the anconeal process of the ulna (Fig. 5).

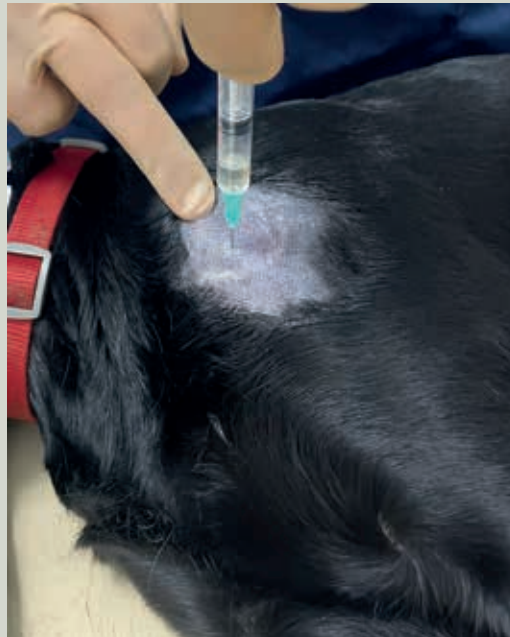
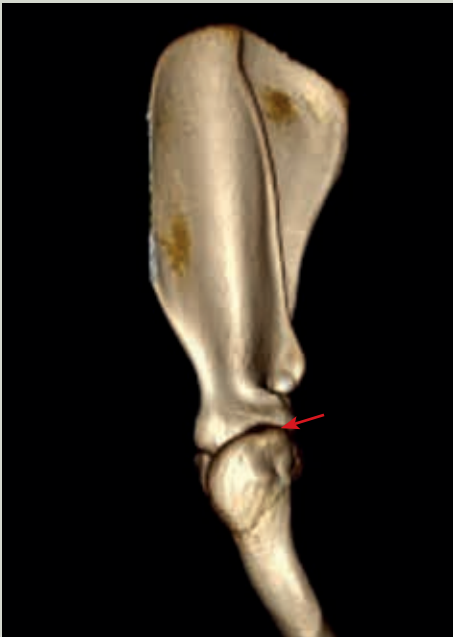
Figure 3. Shoulder arthrocentesis via lateral approach. The acromial process of the scapula is used as an anatomical landmark. The hypodermic needle is introduced immediately distal to the acromial process and directed perpendicular to the scapula. In the image, the surgeon is indicating the acromial process with their index finger.

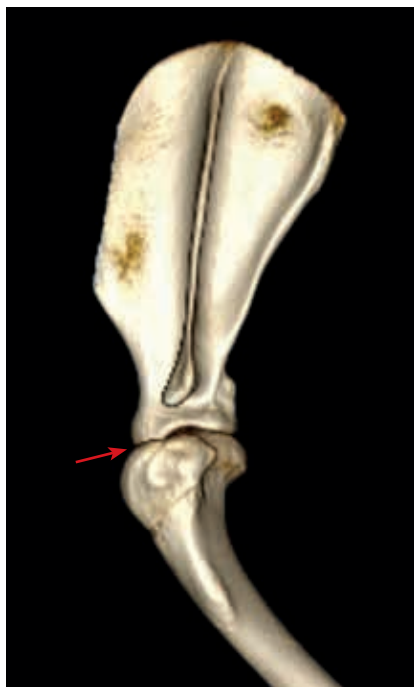

Figure 4. Shoulder arthrocentesis via cranial approach. The greater tubercle of the humerus is used as anatomical landmark. The needle is introduced immediately medial to the greater tubercle (and distal to the supraglenoid tubercle of the scapula) in a craniocaudal direction.

CARPAL ARTHROCENTESIS

To perform arthrocentesis of the carpal joint, a 25-gauge hypodermic needle 20–40 mm in length is usually utilised. The radiocarpal joint can be localised by palpating the cranial aspect of the carpus while flexing/extending the joint. In healthy patients, a depression can easily be identified when the joint is palpated; however, this may be more

difficult in patients with joint disease due to intra-articular effusion.

Once the carpal joint has been located, the joint is flexed 90 degrees, the hypodermic needle is inserted perpendicular to the joint (Fig. 6) and synovial fluid is aspirated. When inserting the needle, the cephalic vein crossing the joint dorsally should be avoided; therefore, the needle should be inserted medial to said vein and to the tendon of the common digital extensor muscle. Sometimes a synovial fluid sample can be taken from the intercarpal joint using the same technique (Fig. 7).

HIP ARTHROCENTESIS

Locating the coxofemoral joint to perform arthrocentesis can be challenging, as it has a small joint space that is found several centimetres deep. Using the greater trochanter of the femur as an anatomical landmark, the hypodermic needle is introduced slightly craniodorsal to it. A 22-gauge, 80 mm long needle is usually used, and the needle is directed somewhat ventrally as it is advanced in the direction of the joint (Fig. 8). Sometimes it is useful to rotate internally, apply traction distally and abduct the limb to introduce the needle into the coxofemoral joint.

STIFLE ARTHROCENTESIS

The two most commonly used techniques to perform arthrocentesis of the stifle joint are the lateral technique and

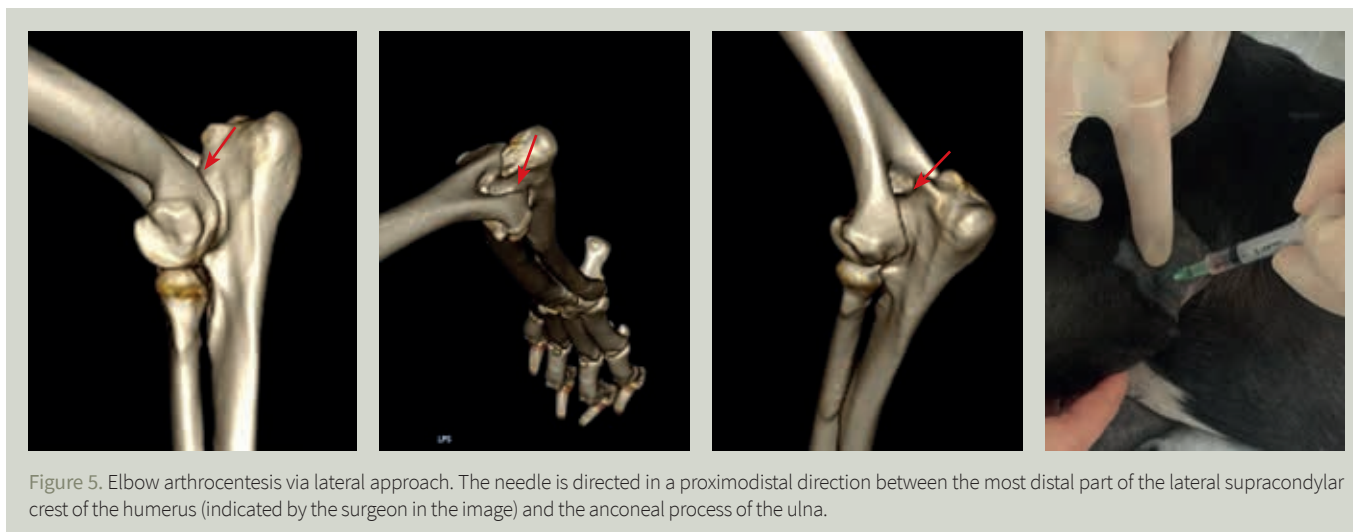


Figure 5. Elbow arthrocentesis via lateral approach. The needle is directed in a proximodistal direction between the most distal part of the lateral supracondylar crest of the humerus (indicated by the surgeon in the image) and the anconeal process of the ulna.

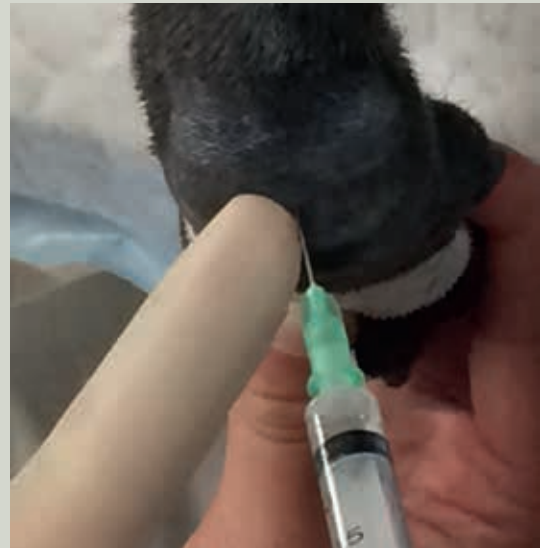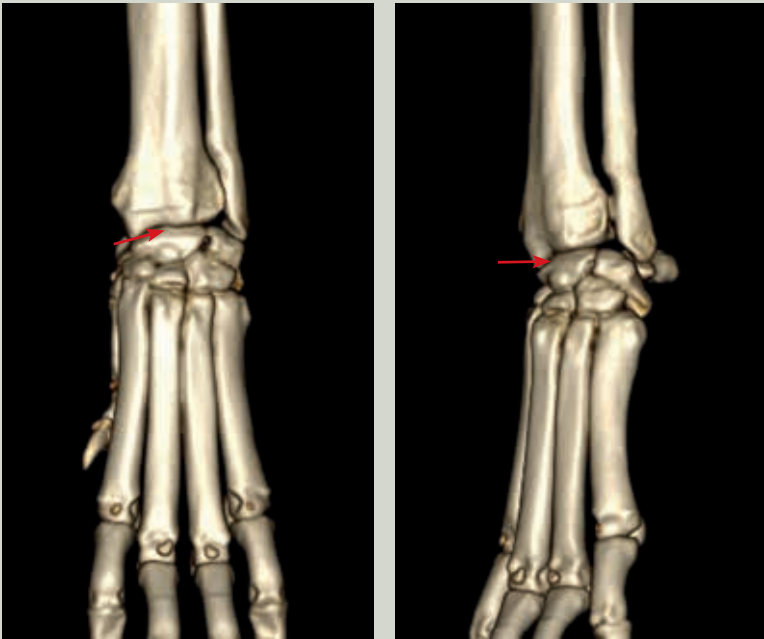


Figure 6. Antebrachiocondylar joint arthrocentesis. The joint is flexed 90 degrees and the hypodermic needle is introduced perpendicular to it.

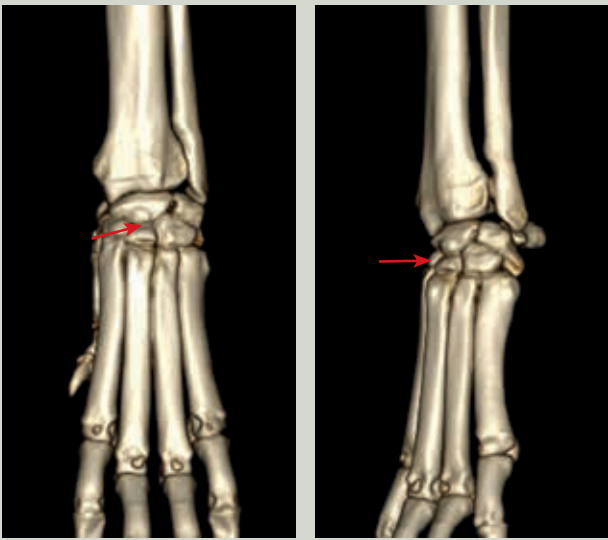


Figure 7. Intercarpal joint arthrocentesis. The hypodermic needle is introduced perpendicular to the joint.

the dorsal technique (the latter is preferred and routinely applied by the author). In both cases, the patient is placed in lateral recumbency, and a 22-gauge hypodermic needle, 40 mm in length, is usually used.

In the lateral technique, the limb is flexed slightly and the patellar ligament is used as an anatomical reference to

introduce the needle. The needle is inserted immediately lateral to the patellar ligament, at the midpoint between the patella and the tibial tuberosity, with an orientation perpendicular to the joint (Fig. 9).

In the dorsal technique, the limb is extended or very slightly flexed. The hypodermic needle is introduced immediately lateral to the patellar ligament, in its distal third, in a distoproximal direction. Therefore, the hypodermic needle enters the joint immediately caudal to the patella, in the trochlear groove of the femur (Fig. 10).

TARSAL ARTHROCENTESIS

Arthrocentesis of the tarsal joint can be performed via a cranial or a caudolateral approach. A 25-gauge needle, 20–40 mm in length, is used regardless of the approach.

In the cranial approach, the tibiotarsal joint should be palpated and located via flexion and extension movements. Once the joint has been identified, the hypodermic needle is directed in a craniocaudal direction perpendicular to the joint (Fig. 11).

In the caudolateral approach, the lateral malleolus of the fibula and the calcaneus are used as anatomical landmarks. In this case, the tarsal joint should be slightly flexed and the hypodermic needle inserted immediately medial to the lateral malleolus of the fibula (Fig. 12).

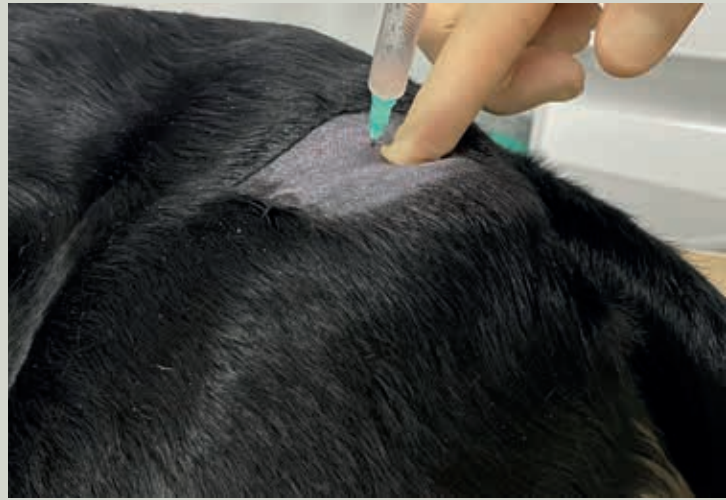
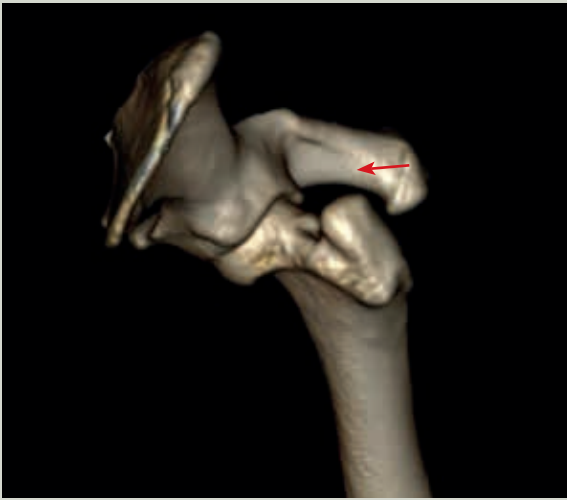
Figure 8. Coxofemoral joint arthrocentesis. The greater trochanter of the femur (indicated by the surgeon in the image) is used as anatomical landmark. The hypodermic needle is introduced slightly craniodorsal to the greater trochanter and directed with a slightly ventral orientation.

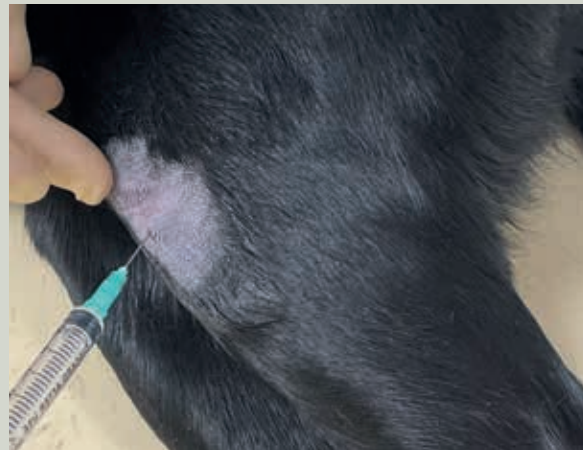
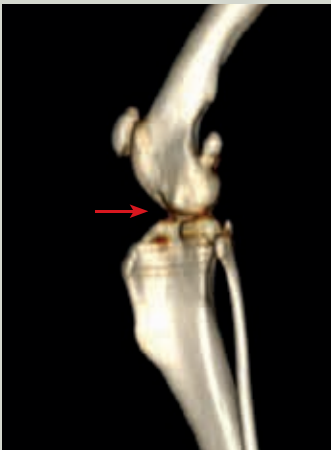
Figure 9. Stifle arthrocentesis via lateral approach. The needle is inserted immediately lateral to the patellar ligament, at the midpoint between the patella and the tibial tuberosity, with an orientation perpendicular to the joint.

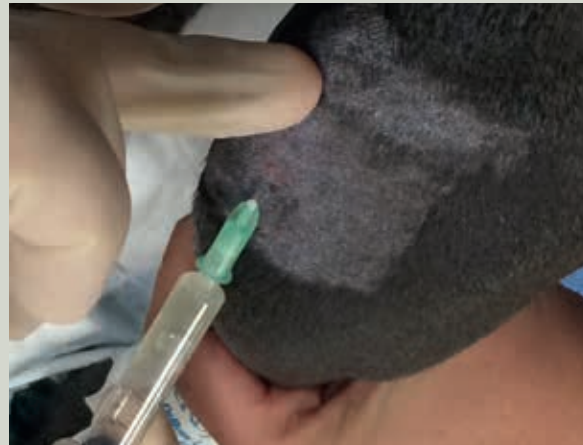
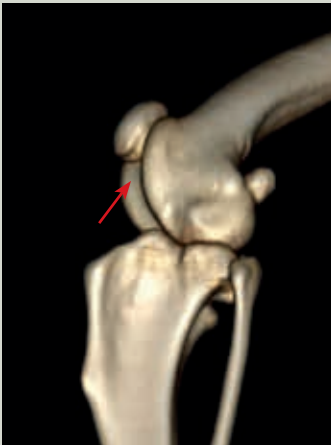
Figure 10. Stifle arthrocentesis via dorsal approach. The hypodermic needle is introduced immediately lateral to the patellar ligament, in its distal third, and is directed immediately caudal to the patella (indicated by the surgeon in the image), in the trochlear groove of the femur.

SYNOVIAL FLUID ANALYSIS

Synovial fluid is an ultrafiltrate of plasma with hyaluronic acid. Analysis of synovial fluid is based on subjective qualitative assessment and on cytological and microbiological evaluation (culture and antibiogram). When synovial fluid is analysed in an external laboratory, it is recommended to transport it at 4 °C within 24 hours (Harris and Santangelo, 2020).

The cytological analysis includes determining the total cell count, the differential cell count and the proportion of mononuclear cells (lymphocytes, macrophages and synoviocytes) and polymorphonuclear cells (neutrophils). Once the synovial fluid has been obtained, the sample can be smeared on slides and placed in sterile tubes (glucose, lactate, total protein, mucin clot test and microbiological analysis), EDTA tubes (total cell count, cytology and total protein), heparin tubes (total cell count, total protein and mucin clot test) and culture media (if septic arthritis is suspected).

The number of samples that need to be sent for analysis depends on the amount of synovial fluid obtained and on the clinical suspicion. If a very small sample is available (1–2 drops), the author performs at least a smear on a slide for cytological examination. If the sample quantity is more abundant, the author routinely sends fresh smears on several slides, a sample preserved in EDTA, a sample in a sterile tube and a sample in a culture medium with blood (if septic arthritis is suspected).

The following parameters should be considered when analysing synovial fluid:

- **Volume.** The normal volume of synovial fluid in a joint depends on the size of the patient and the size of the joint. In general terms, the volume of synovial fluid should be very low and a volume greater than 0.5–1 ml is considered suggestive of arthropathy (Clements, 2006).

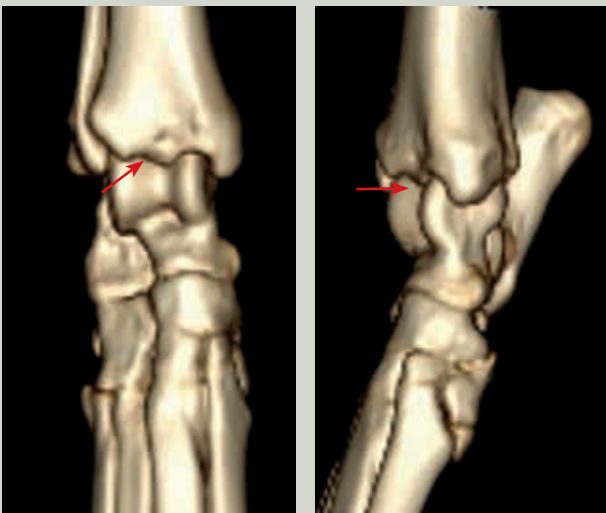

Figure 11. Tibiotarsal joint arthrocentesis via cranial approach. The hypodermic needle is directed in a craniocaudal direction perpendicular to the joint.

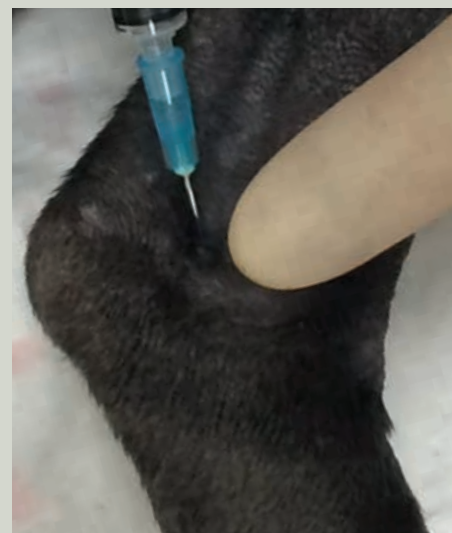
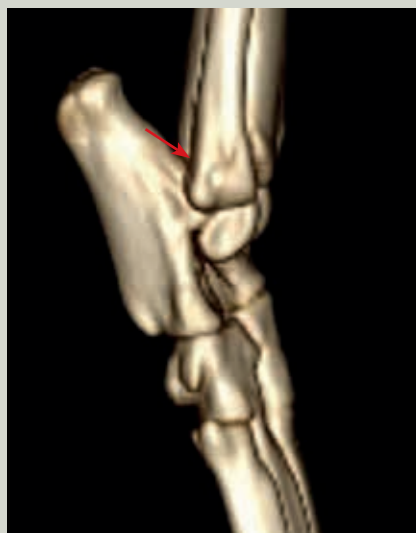
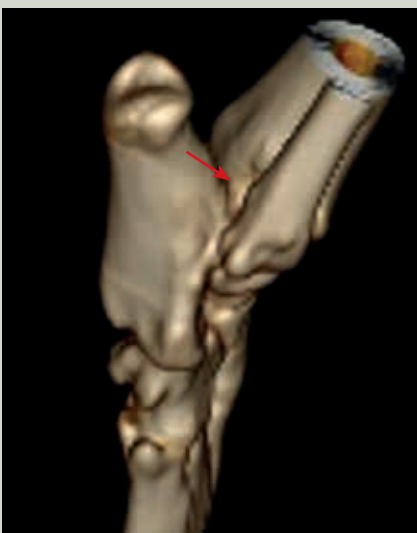Figure 12. Tibiotarsal joint arthrocentesis via caudolateral approach. The hypodermic needle is introduced immediately medial to the lateral malleolus of the fibula (indicated by the surgeon in the image).

- **Colour.** Normal synovial fluid should be clear (although it may occasionally have a pale yellow colour). In the presence of joint disease, the synovial fluid may be sero-haemorrhagic or haemorrhagic, have a yellow orange colour (xanthochromia indicative of previous bleeding) or have a yellow white colour (suggestive of inflammatory arthropathy). A sample free of iatrogenic blood contamination should be obtained in order to differentiate whether the colour change is due to a pathological condition or due to sample collection (Fig. 13).
- **Viscosity.** Normal synovial fluid is viscous. Its degree of viscosity can be assessed subjectively by placing a drop of synovial fluid between two fingers and assessing the length of the thread the fluid forms when spreading the fingers apart before it breaks (Fig. 14). Normal synovial fluid should be able to spread about 2–4 cm before breaking. In joint disease, the synovial fluid is less viscous, so the length of fluid thread between the fingers is less than 2 cm.
- **Turbidity.** Synovial fluid is clear/transparent, so increased turbidity is considered pathologic. An increase in synovial fluid turbidity indicates an increase in cellularity (Fig. 15).




Figure 13. Synovial fluid sample of whitish colour, suggestive of joint disease.

- **Laboratory analysis:**

- **Total cell count:**

Normal synovial fluid has a very low total cellularity, of less than $2 \times 10^9/l$. Increased cellularity in the synovial fluid suggests the presence of joint disease. In inflammatory arthropathies, the increase in synovial fluid cell count can be very marked, reaching a cellularity of $250\text{--}350 \times 10^9/l$.



Figure 14. Subjective assessment of the degree of viscosity of the synovial fluid. A drop is placed between the fingers and, when they are separated, the length of the fluid thread is measured before it breaks.

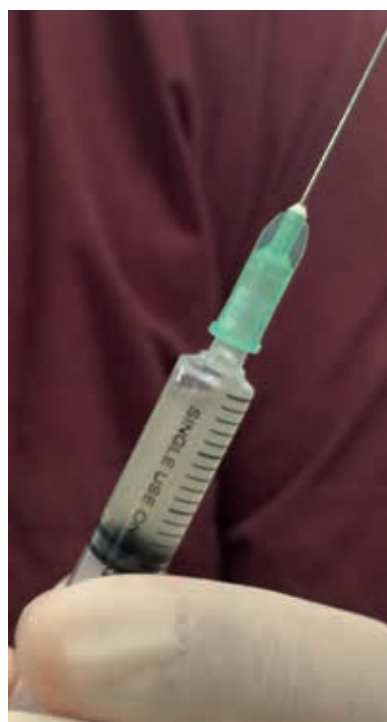


Figure 15. Synovial fluid sample with an increased degree of turbidity, suggestive of joint disease.

Total cell count can be carried out with an automatic analyser. To estimate this cell count, however, a direct smear of synovial fluid can be performed and the mean number of cells in 10 microscopic fields can be counted with a high-power objective lens (40×). Multiplying the average number of cells per microscopic field by 1000 gives an estimated number of cells per microlitre (Harris and Santangelo, 2020). Estimating with a direct smear is less accurate, so this value should only be used as a guideline in cases where an automatic analyser is not available.

■ **Differential cell count:**

If sufficient sample volume is obtained, it should be placed in an EDTA tube to preserve cell morphology for subsequent analysis. If the volume is very small, 1–2 drops of synovial fluid are smeared on a slide and stained with a Diff-Quik-type rapid stain.

Cytological analysis of the synovial fluid sample is probably the most important factor in differentiating the various types of arthropathy.

When a cytological study of the synovial fluid is performed, the proportion of each cell type must be determined, which makes it possible to differentiate whether an arthropathy has an inflammatory or noninflammatory origin. Noninflammatory joint diseases have a

predominance of mononuclear cells (lymphocytes, macrophages and synoviocytes) (Fig. 16a), whereas inflammatory arthropathies have an increased number of polymorphonuclear cells (neutrophils) (Fig. 16b). If these are immune-mediated inflammatory arthropathies, the neutrophils have a nondegenerate appearance, whereas in case of infectious inflammatory joint diseases, neutrophils with a degenerated appearance may be present.

Although uncommon, the cytological analysis of synovial fluid can be pathognomonic when cells of a tumoural origin or intracellular bacteria are present in the sample.

■ **Microbiological culture:**

A microbiological culture of synovial fluid should be performed whenever septic arthritis is suspected. The false negative rate of synovial fluid cultures is very high in septic arthritis, so it is recommended to culture synovial fluid in blood media (Fig. 17).

■ **Mucin clot test.** The purpose of this test is to semiquantitatively determine the hyaluronic acid content of synovial fluid. To do so, acetic acid is mixed with the synovial fluid, causing a polymerisation of the hyaluronic acid. The result is the formation of a precipitate, which is evaluated for its quantity and consistency. Slower precipitate formation is associated with pathological or inflammatory conditions in the joint. This test is rarely used.

■ **Lactate.** A recent study (Proot et al., 2015) evaluated the lactate concentration in the synovial fluid of patients with joint disease. This study found that patients with septic arthritis had higher lactate levels in their synovial fluid

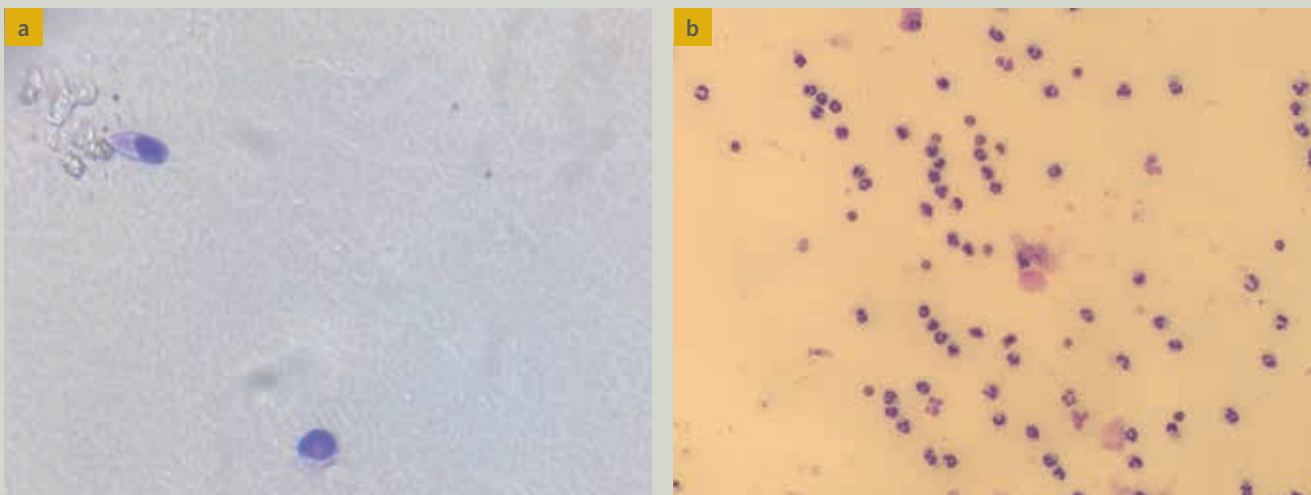


Figure 16. Cytological image of two synovial fluid samples. Sample from a patient with a noninflammatory arthropathy that has a predominance of mononuclear cells (a). Sample from a patient with an inflammatory arthropathy that has a predominance of neutrophils (b).



Figure 17. Blood culture medium used for the microbiological analysis of synovial fluid.

than was found in other types of arthropathies or in normal synovial fluid. Thus, a synovial fluid lactate result higher than 6.5 mmol/l was established as a predictive value for septic arthritis.

- Total protein.** A determination of the protein content of synovial fluid can be performed using a refractometer or automatic counts. Values between 1.5 and 3 g/dl are considered normal (MacWilliams and Friedrichs, 2003). Its clinical use is limited, although an increase in this value is considered indicative of the presence of arthropathy. When assessing this result, it should be considered whether the blood:EDTA ratio in the collection tube was adequate, as an excess of EDTA due to a low volume of blood in the tube will lead to a false positive result.

The common findings observed in the synovial fluid of patients with the most common arthropathies are

summarised in Table 1. Normal synovial fluid is viscous, and has a clear or pale yellow colour. From a cytological point of view, the synovial fluid in a normal joint has a very low cellularity ($<2 \times 10^9/l$) and the cell population is predominantly mononuclear (94–100 %), with a low population of nondegenerate neutrophils (0–6 %).

In the presence of noninflammatory degenerative joint disease (osteoarthritis), the synovial fluid is usually also clear or pale yellow, but it is present in greater volume and has lower viscosity and higher cellularity ($2\text{--}5 \times 10^9/l$). The predominant cell population in degenerative arthropathies is also mononuclear (88–100 %), and there may be a low population of nondegenerate neutrophils (0–12 %).

When a patient has a noninfectious inflammatory arthropathy, the synovial fluid is denser, with greater volume, lower viscosity and very high cellularity ($4\text{--}370 \times 10^9/l$). Regarding the percentage of mononuclear cells and neutrophils, very variable ranges have been described (5–85 % and 15–95 %, respectively). It should be noted that it is very common for noninfectious inflammatory arthropathies to have an immune-mediated origin and affect several joints. Therefore, it is necessary to take samples from several joints if an immune-mediated arthropathy is suspected (it is recommended to take samples from at least four different, preferably distal, joints).

If immune-mediated joint disease is suspected, it is recommended to take samples from at least four different joints, preferably distal.

In the presence of an infectious inflammatory arthropathy (septic arthritis), the synovial fluid is denser, with greater volume and lower viscosity. From a cytological point of view, the synovial fluid in these cases is largely composed of neutrophils ($>90\%$), both degenerated and nondegenerated.

TABLE 1. Common findings in synovial fluid in the most frequent arthropathies.

	Volume	Viscosity	Colour	Turbidity	Proteins	Total cell count	Mononuclear cells	Neutrophils
Normal	<0.5–1 ml	Viscous	Colourless, pale yellow	Clear, transparent	1.5–3 g/dl	$2 \times 10^9/l$	>94 %	<6 %
Osteoarthritis	Normal/↑	Viscous/↓	Colourless, pale yellow	Clear, transparent	>3 g/dl	$2\text{--}5 \times 10^9/l$	>88 %	<12 %
Immune-mediated arthritis	↑/↑↑	↓	Yellow, white, serosanguineous	Transparent, turbid	>3 g/dl	$4\text{--}370 \times 10^9/l$	5–85 %	15–95 %
Septic arthritis	↑/↑↑	↓	Yellow, white, serosanguineous	Turbid	>3 g/dl	$40\text{--}267 \times 10^9/l$	<10 %	>90 %

Occasionally, the presence of bacteria can be seen in the cytological examination, although this is not common. If bacteria are present in the sample, they are only pathognomonic of septic arthritis if they are located intracellularly; otherwise, they could be due to sample contamination.

COMPLICATIONS

The complication rate of arthrocentesis is extremely low when the technique is performed properly.

The most frequent complication is iatrogenic blood contamination of the sample. If mild, the results may be interpretable, as the pathologist can sometimes assess the cell count by comparing it to the peripheral blood count.

Although very rare, another potential complication is iatrogenic septic arthritis. When performing an arthrocentesis, it is essential to follow a strict aseptic protocol and avoid performing this test if the patient presents signs of dermatitis or pyoderma. The incidence of this complication when performing arthrocentesis in small animals is unknown, but in horses it has been reported in less than 0.1 % of cases (Steel et al., 2013).

Septic arthritis (by Miguel Solano)

Septic arthritis is an active joint infection, usually of bacterial origin, which typically results in inflammation, swelling, pain and lameness (Mielke et al., 2018) (Videos 1 and 2). Infection can occur by direct inoculation, by haematogenous spread or by extension of a local infection. The majority of bacterial septic arthritis cases manifest as an acute or chronic monoarthropathy.

Several different bacteria, most commonly *Staphylococcus intermedius*, *Staphylococcus aureus* and beta-haemolytic streptococci, have been implicated in bacterial infective arthritis in dogs (Mielke et al., 2018). Males of large-breed dogs are predisposed. The degree of lameness at presentation is variable but can be severe. Joint effusion and a variable periarticular swelling are seen (Fig. 19). Some dogs may present with severe clinical signs of cellulitis.



Video 1. Dog with clinical signs of right thoracic limb lameness related to septic arthritis.

Previous joint surgery has been reported as the most common cause of septic arthritis in a study of 31 dogs (Clements, 2006). Septic arthritis, even in the absence of pyrex-

ia, should be considered as a major differential diagnosis in middle-aged, large-breed dogs with preexisting elbow arthritis that suffer an acute onset of lameness with elbow joint effusion and discomfort (Mielke et al., 2018).

Synovial fluid sampling is strongly recommended (Figs. 18 and 20). Samples for cytology, culture (inoculated into a blood culture medium) and lactate analysis (if available) should be taken. Mielke et al. (2018) reported positive culture results in only 50 % of dogs with suspected septic arthritis. Considering the high number of false negative results, it is recommended to incubate the synovial fluid sample in blood culture media for 24 hours to increase the sensitivity of the test (Miller et al., 2018).

Synovial fluid samples should be taken for cytology, culture and lactate analysis. Incubating the sample in blood culture media improves the sensitivity of culture.

A presumptive diagnosis of bacterial infective arthritis can be made when the synovial fluid collected from a monoarthropathy shows very high nucleated cell counts ($>50 \times 10^9$ cells/ml), predominantly polymorphonuclear cells (Fig. 21), the presence of intracellular bacteria on cytology or a combination of both findings. Synovial fluid lactate concentration is significantly increased in septic arthritis and can be used to rule out this condition in a quick and cost-effective manner (Proot et al., 2015) (Fig. 22).