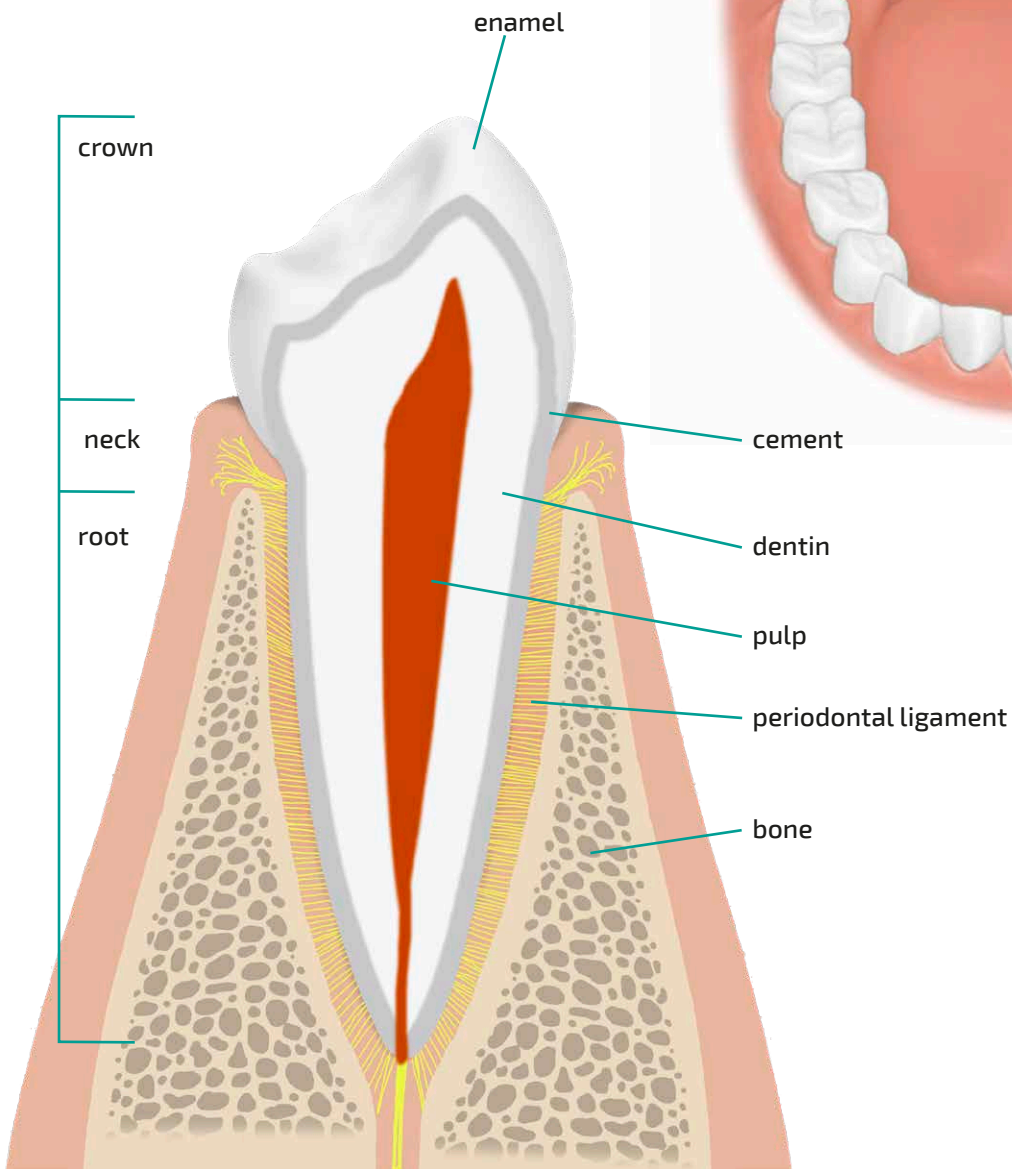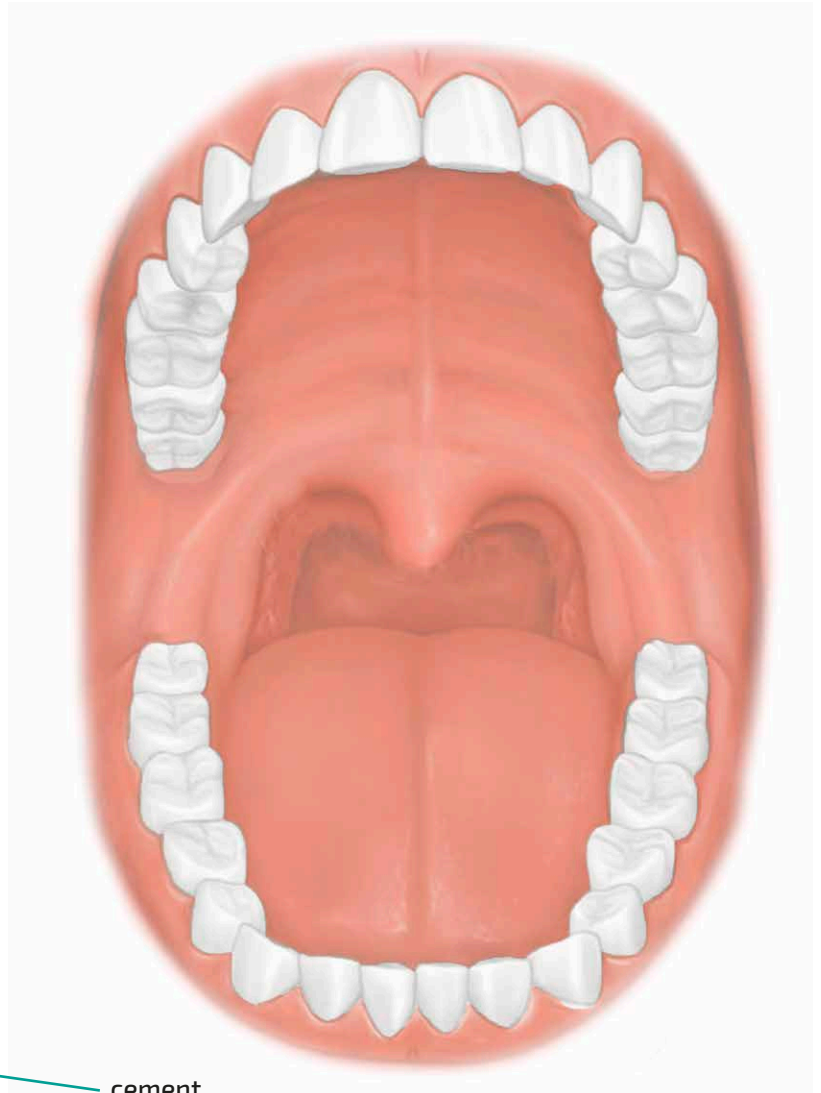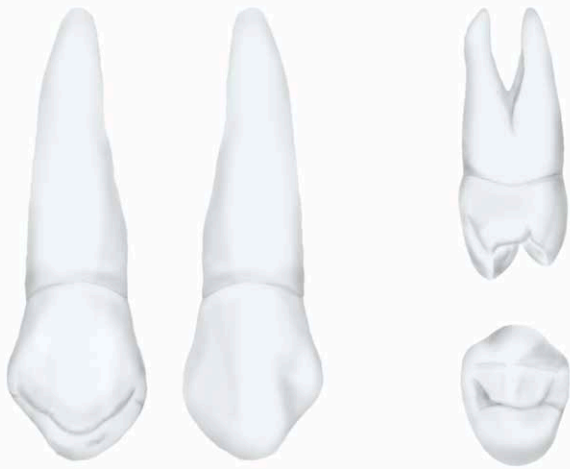


central incisor



first premolar



second molar

