

Anatomia generale
Anatomia sistematica

1-3 **Tavole bonus**
4-21

TB 1-TB 13

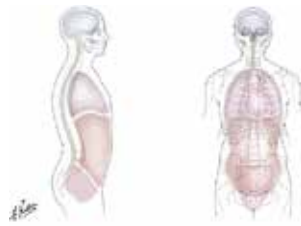Accedi al materiale online



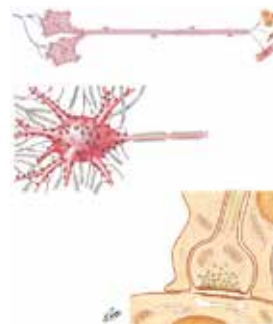
TAVOLE BONUS



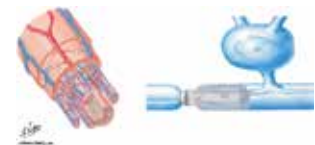TB 1 Apparato pilosebaceo



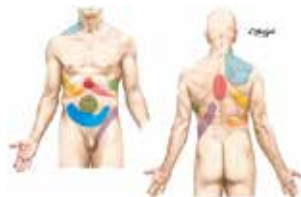TB 2 Principali cavit  corporee



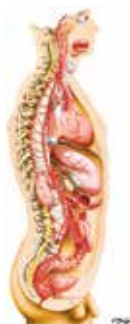TB 3 Neuroni e sinapsi



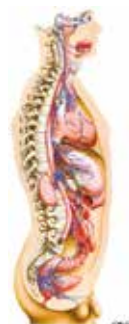TB 4 Caratteristiche di un nervo periferico tipico



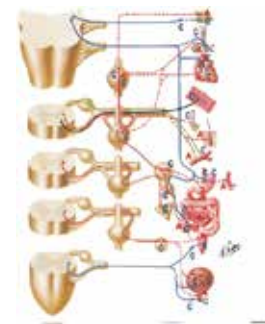
TB 5 Siti del dolore viscerale riferito



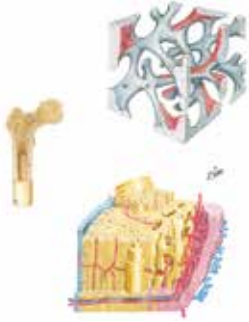

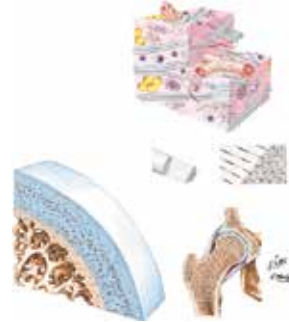
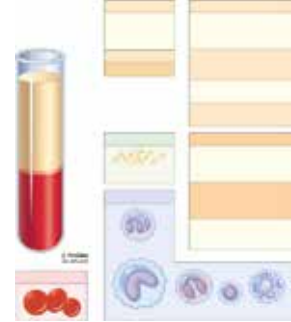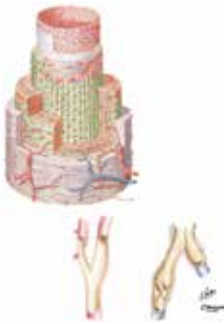
TB 6 Sistema nervoso simpatico: topografia generale

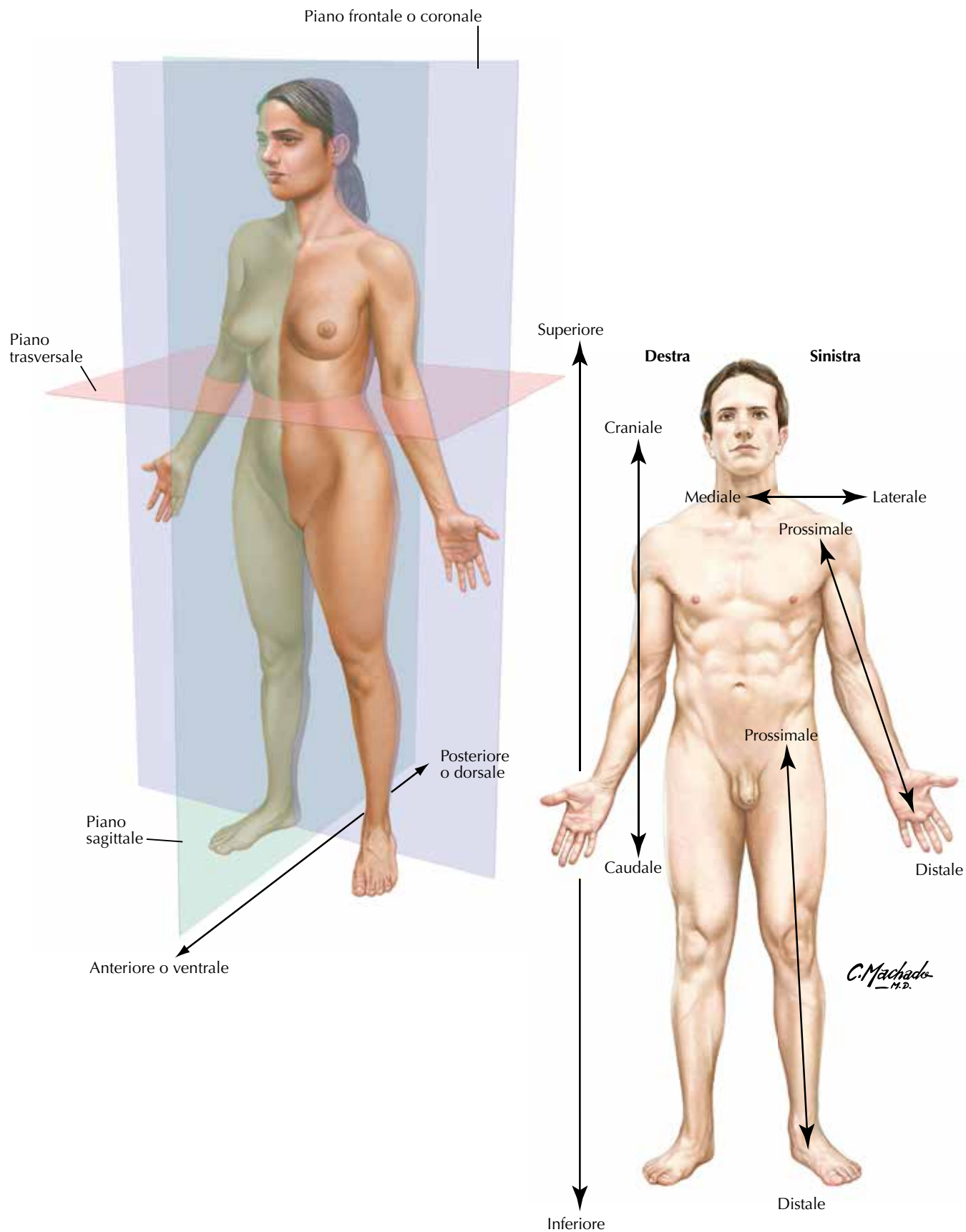


TB 7 Sistema nervoso parasimpatico: topografia generale



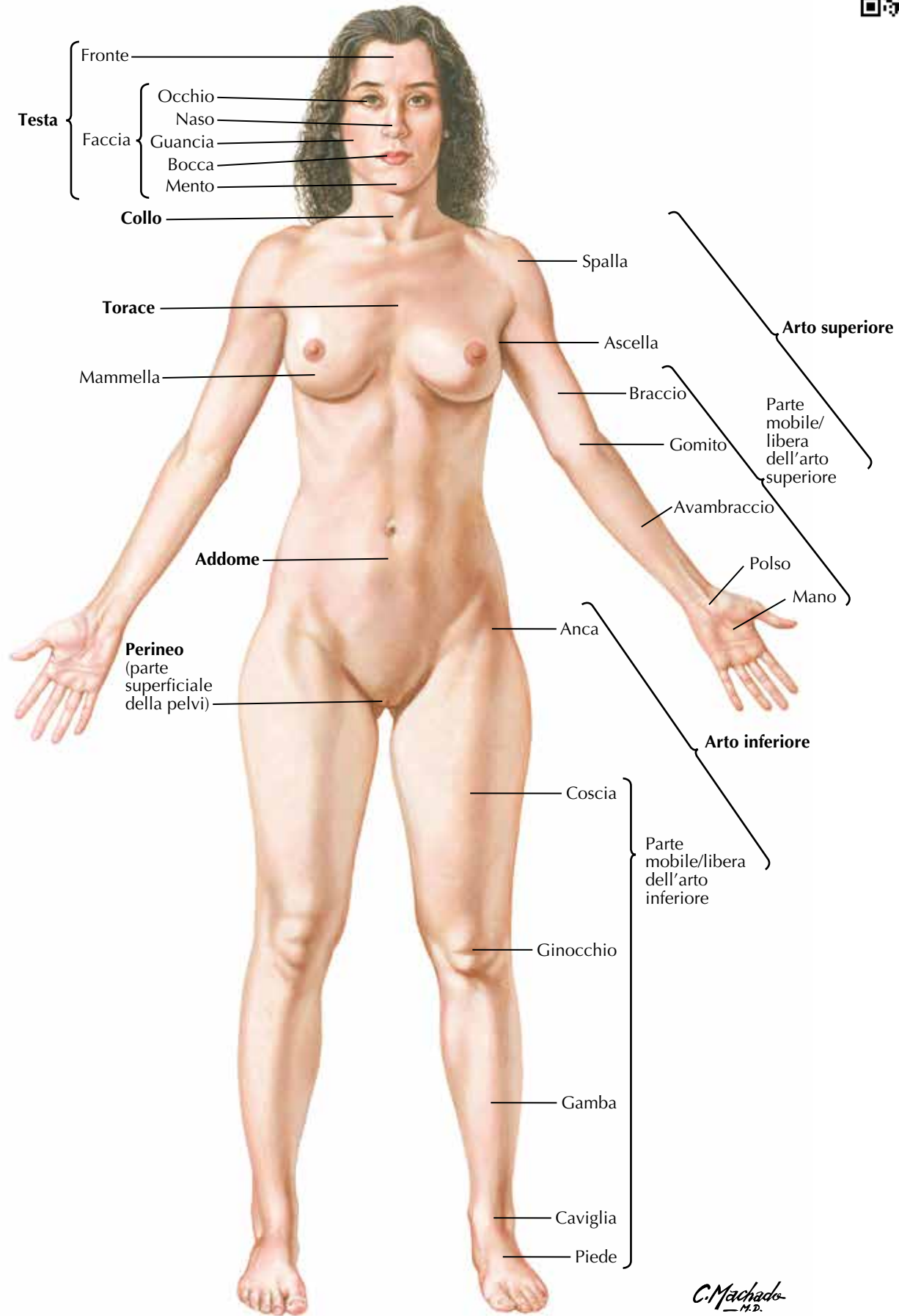
TB 8 Sinapsi colinergiche e adrenergiche: schema

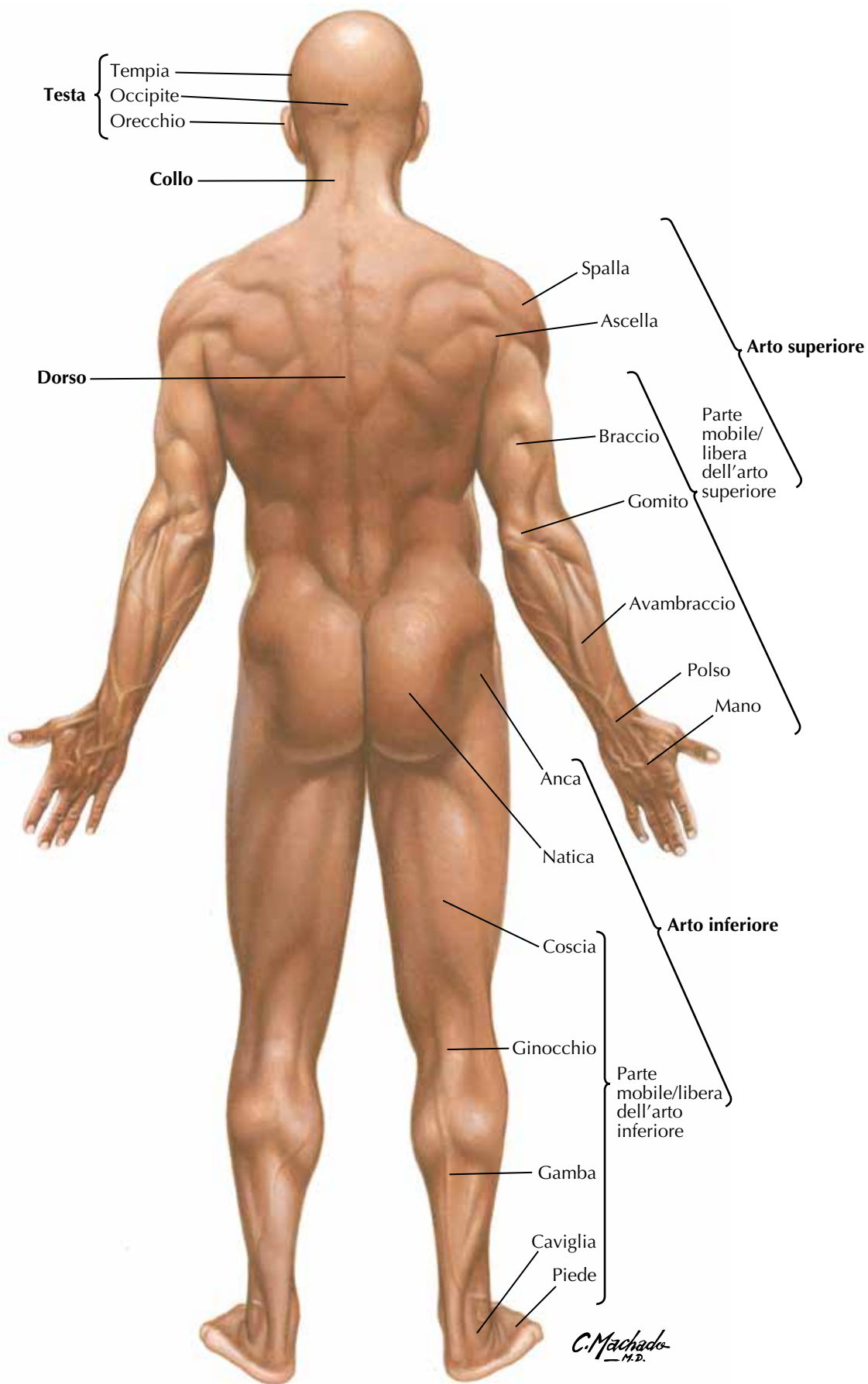
TAVOLE BONUS (*continua*)**TB 9** Struttura dell'osso**TB 10** Struttura del muscolo**TB 11** Articolazioni:
tessuti connettivi
e cartilagine articolare**TB 12** Sistema
cardiovascolare:
composizione del sangue**TB 13** Parete arteriosa





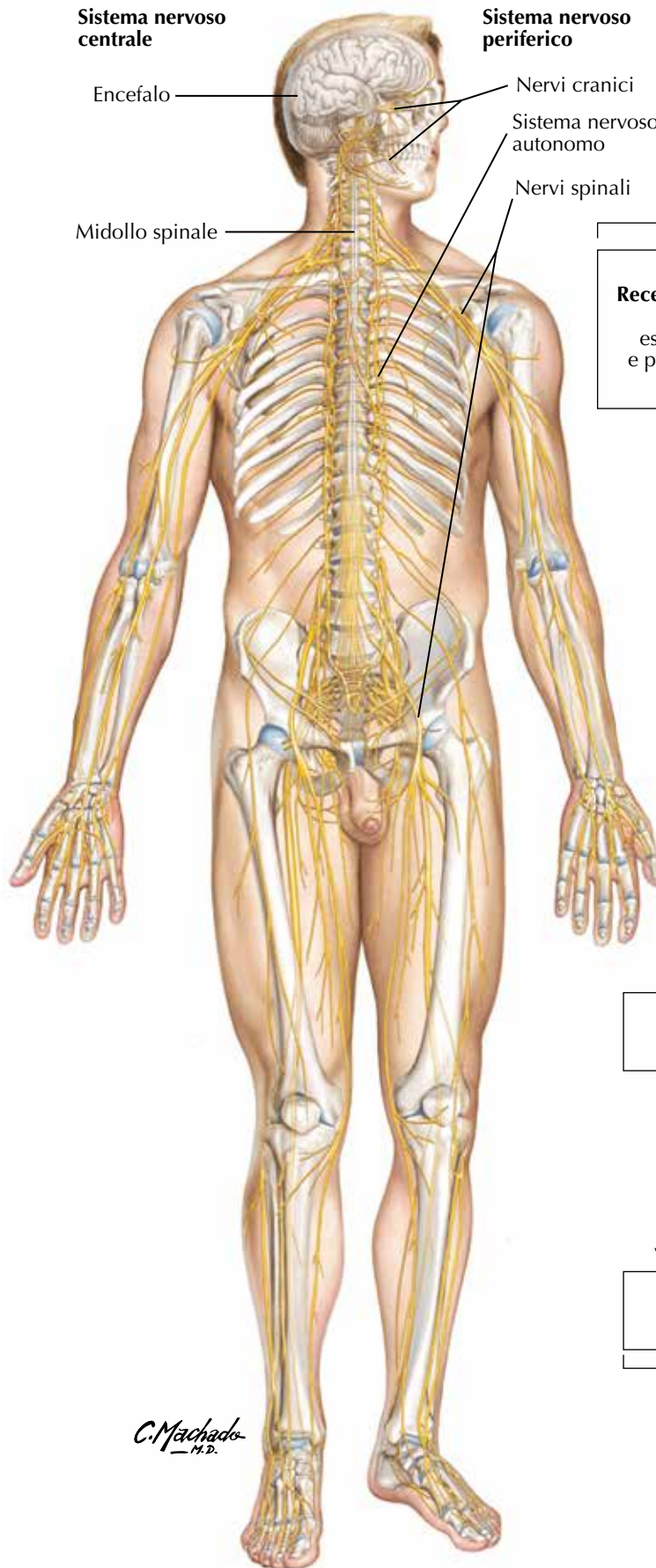
Parti del corpo: veduta anteriore nella femmina



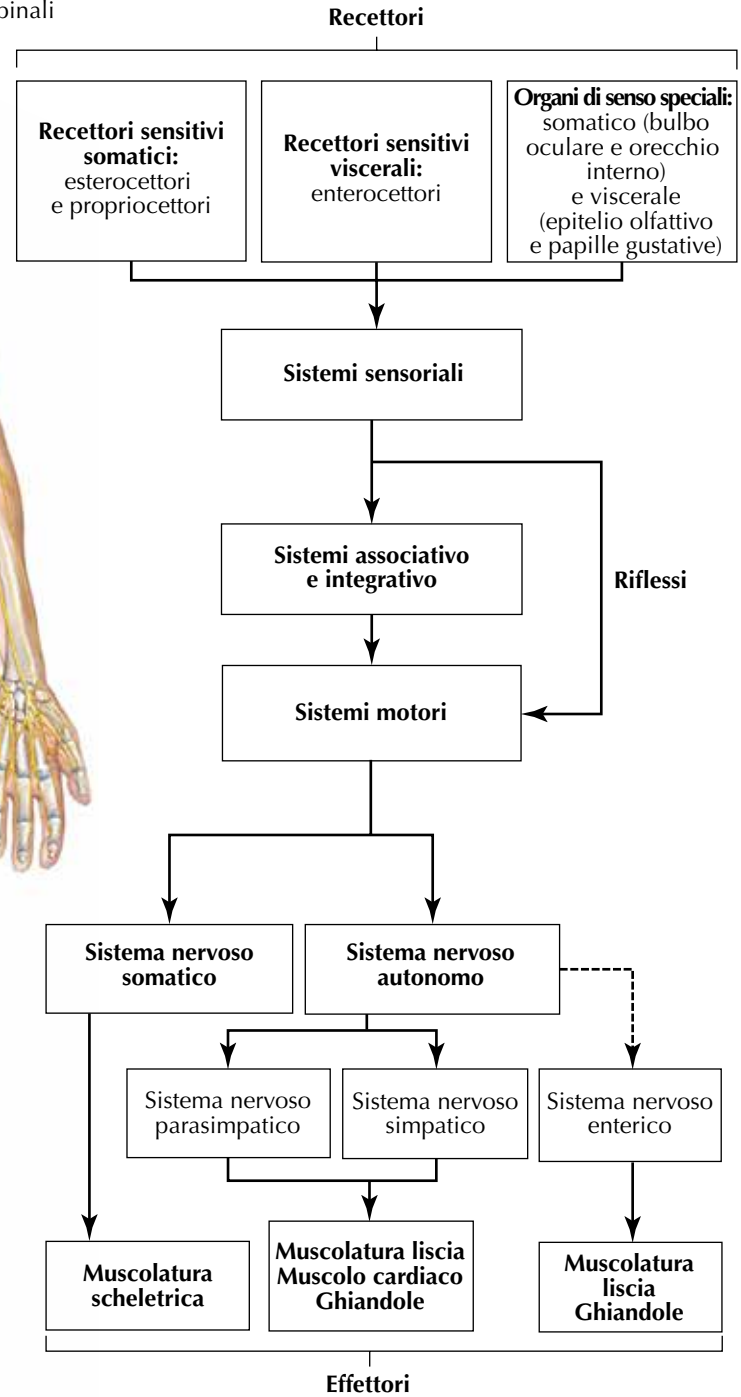


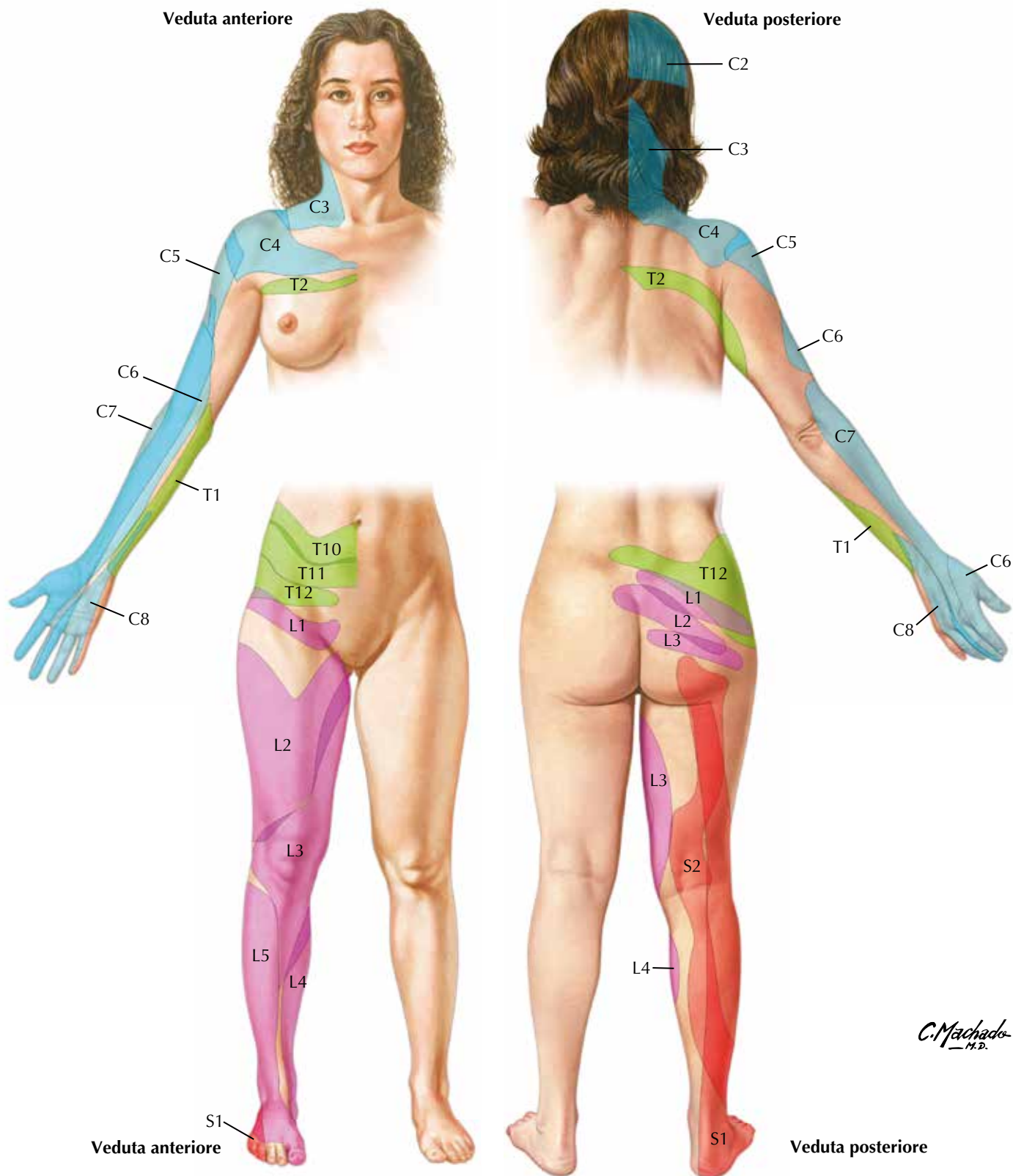


Panoramica del sistema nervoso



C. Machado M.D.



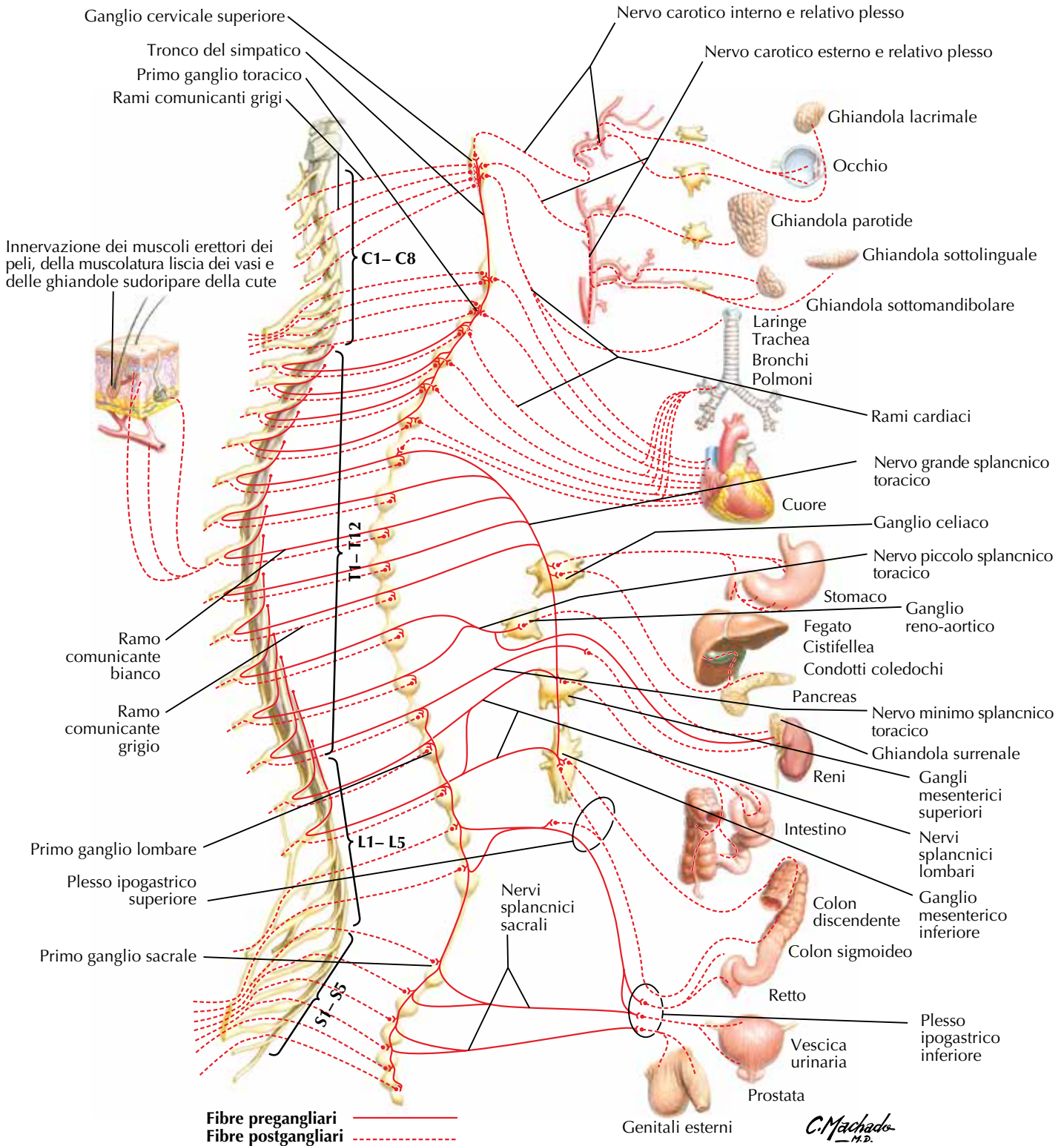


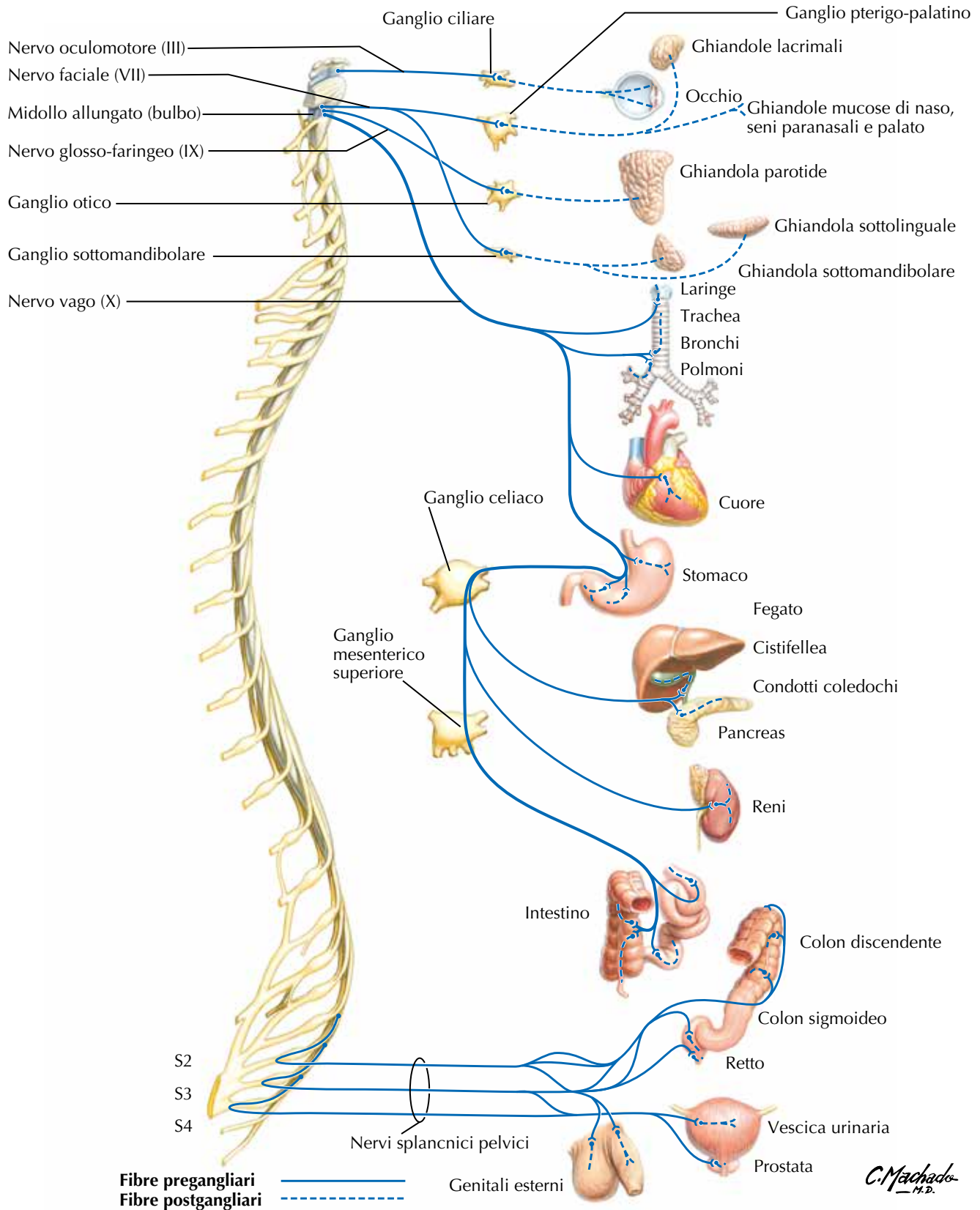
Rappresentazione schematica dei dermatomeri basata sul lavoro di Lee MW, McPhee RW, Stringer MD. An evidence-based approach to human dermatomes. *Cli. Anat.* 2008; 21(5):363-373. doi:10.1002/ca.20636. PMID: 18470936. Notare che le aree rappresentate non hanno valore assoluto e variano in base al soggetto esaminato. S3, S4, S5, e Co che innervano il perineo non sono evidenziati. Si deve inoltre tenere presente che i dermatomeri hanno dimensioni maggiori di quanto illustrato nella figura; in alcune aree le lacune fra territori contigui sono dovute al fatto che i dati in letteratura non sono ben definiti..



Sistema nervoso simpatico: schema

Vedi anche Tavole 229, 249, 341, TB 6, TB 8, TB 52

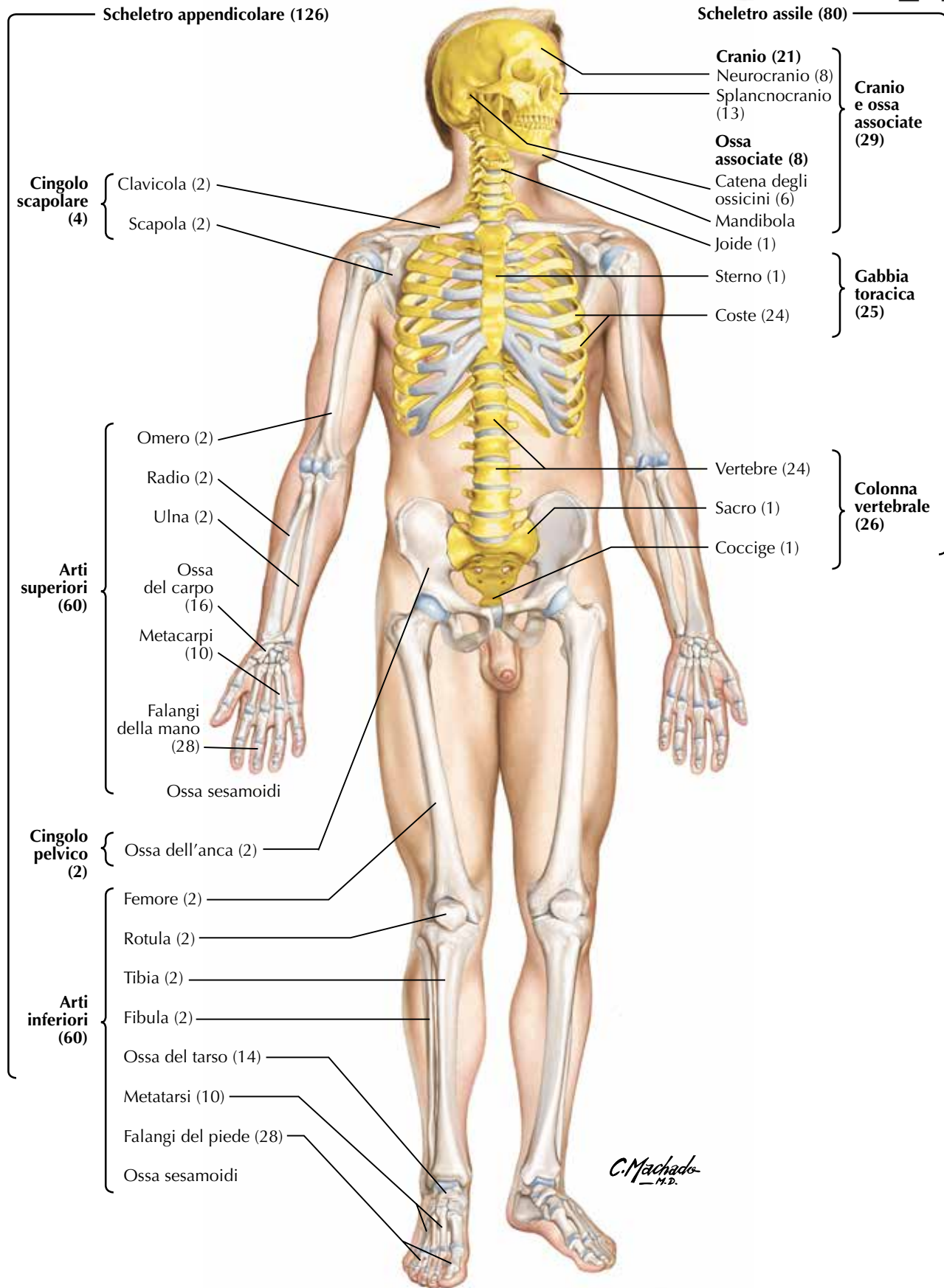




C. Machado M.D.

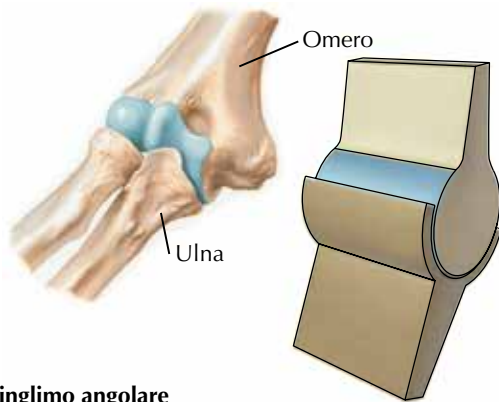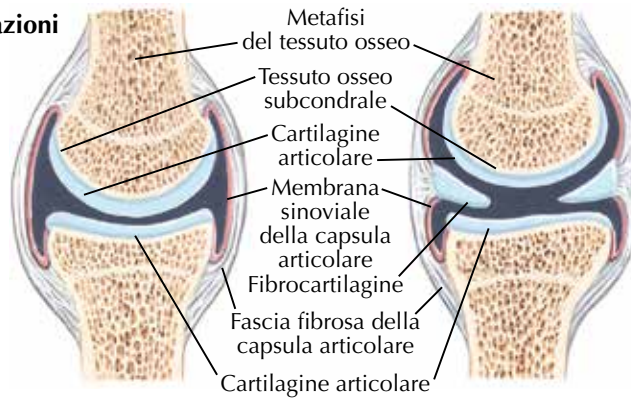


Vedi anche Tavola TB 9

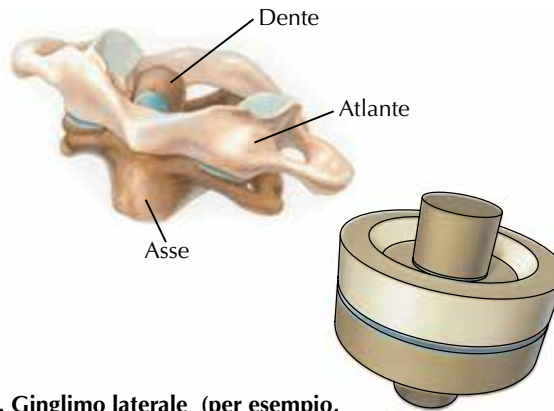




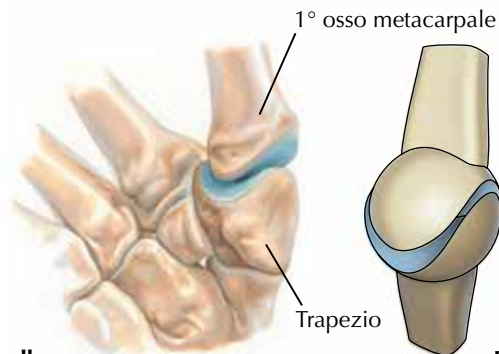
Struttura delle articolazioni sinoviali



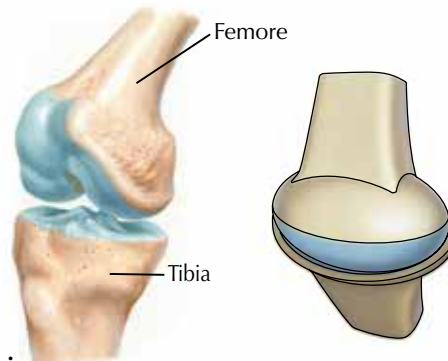
A. Ginglino angolare
(per esempio, articolazione del gomito)



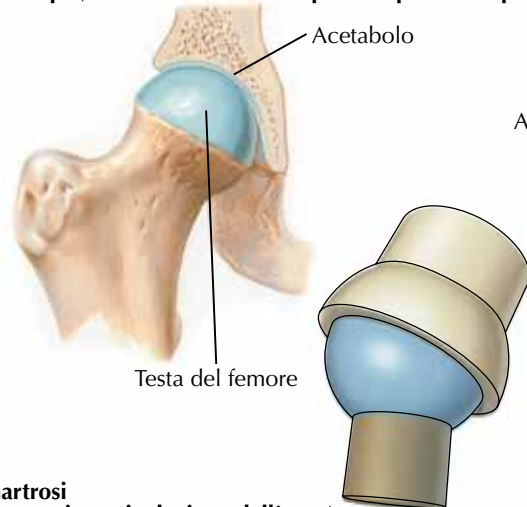
B. Ginglino laterale (per esempio, articolazione a pivot-atlo-epistrofica)



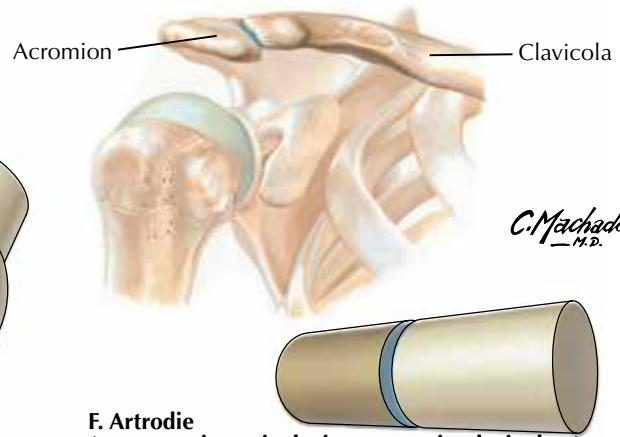
C. A sella
(per esempio, articolazione metacarpale del pollice)



D. Condilartrosi
(per esempio, articolazione del ginocchio)



E. Enartrosi
(per esempio, articolazione dell'anca)



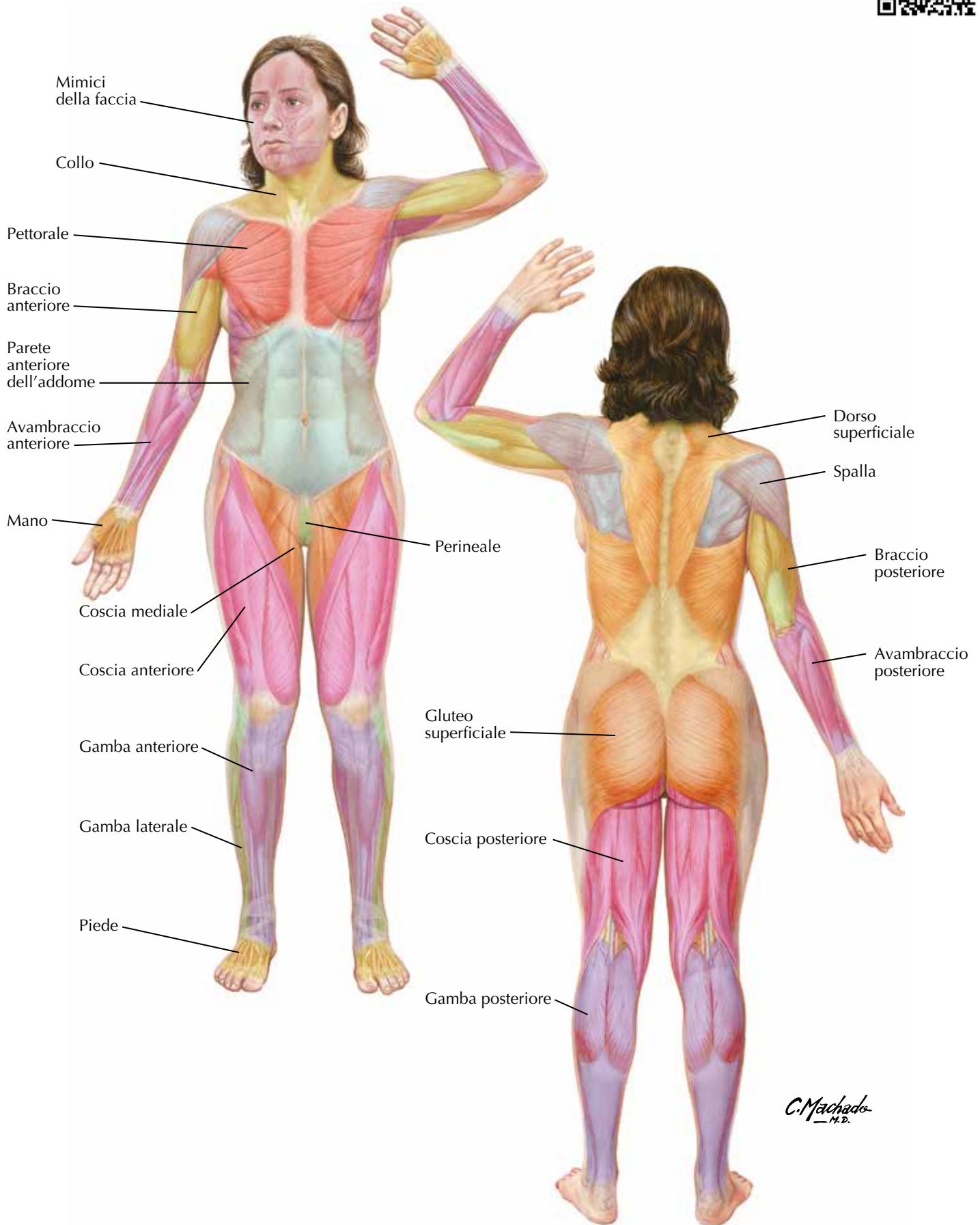
F. Artrodie
(per esempio, articolazione acromio-clavicolare)

*C. Machado
-M.D.*



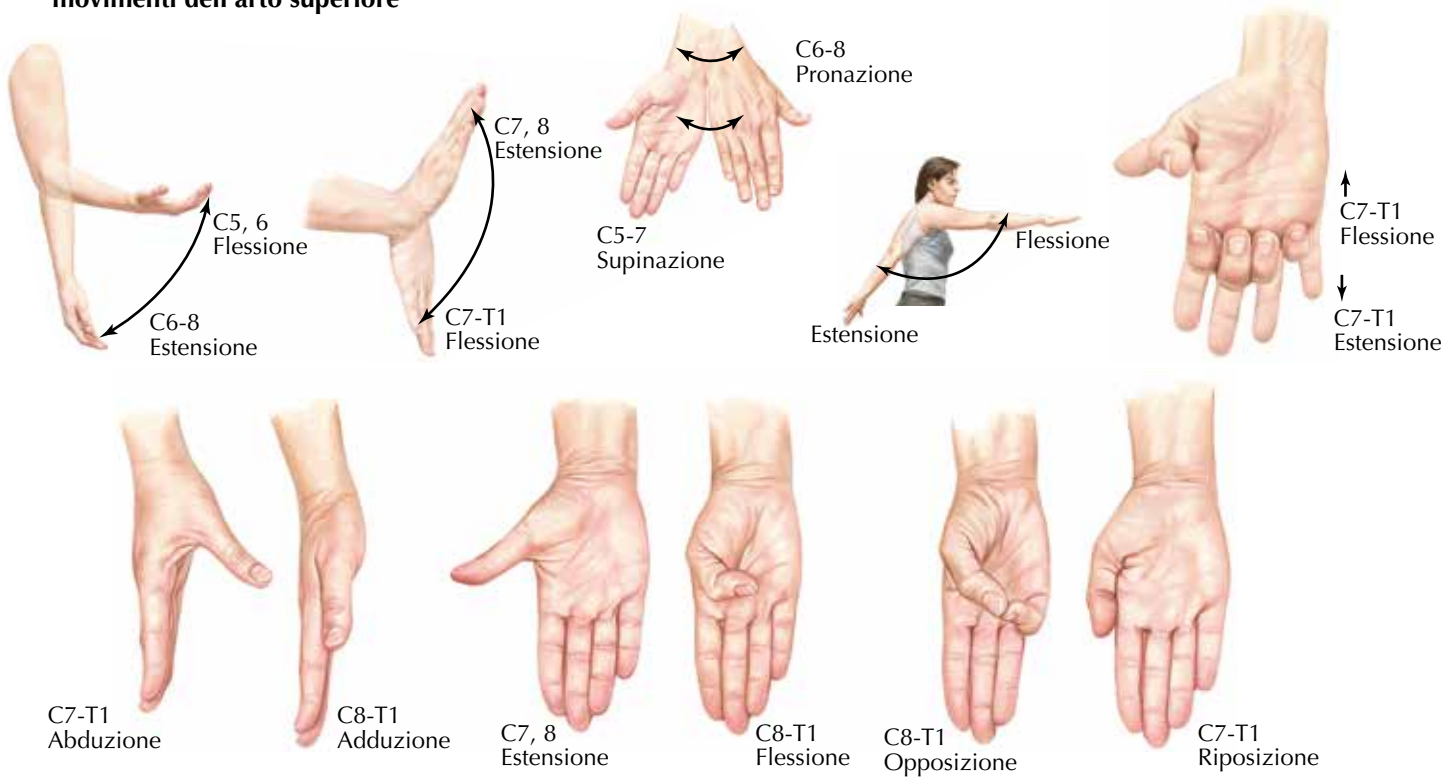
Panoramica del sistema muscolare

Vedi anche **Tavola TB 10**

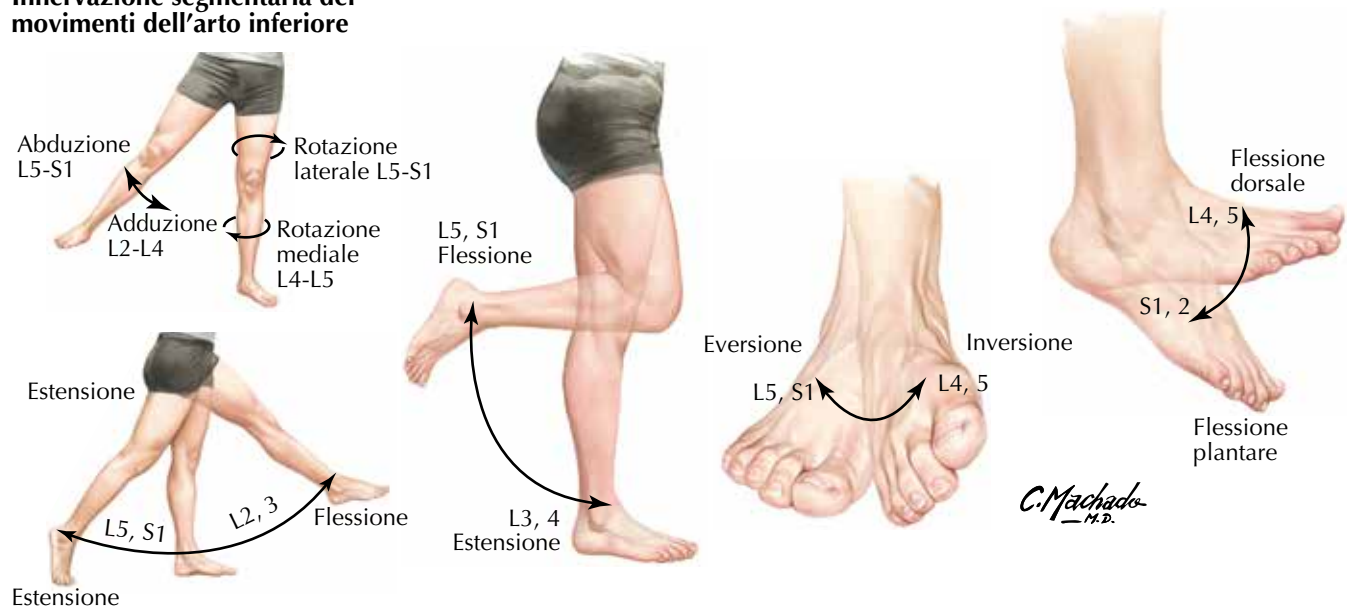




Innervazione segmentale dei movimenti dell'arto superiore



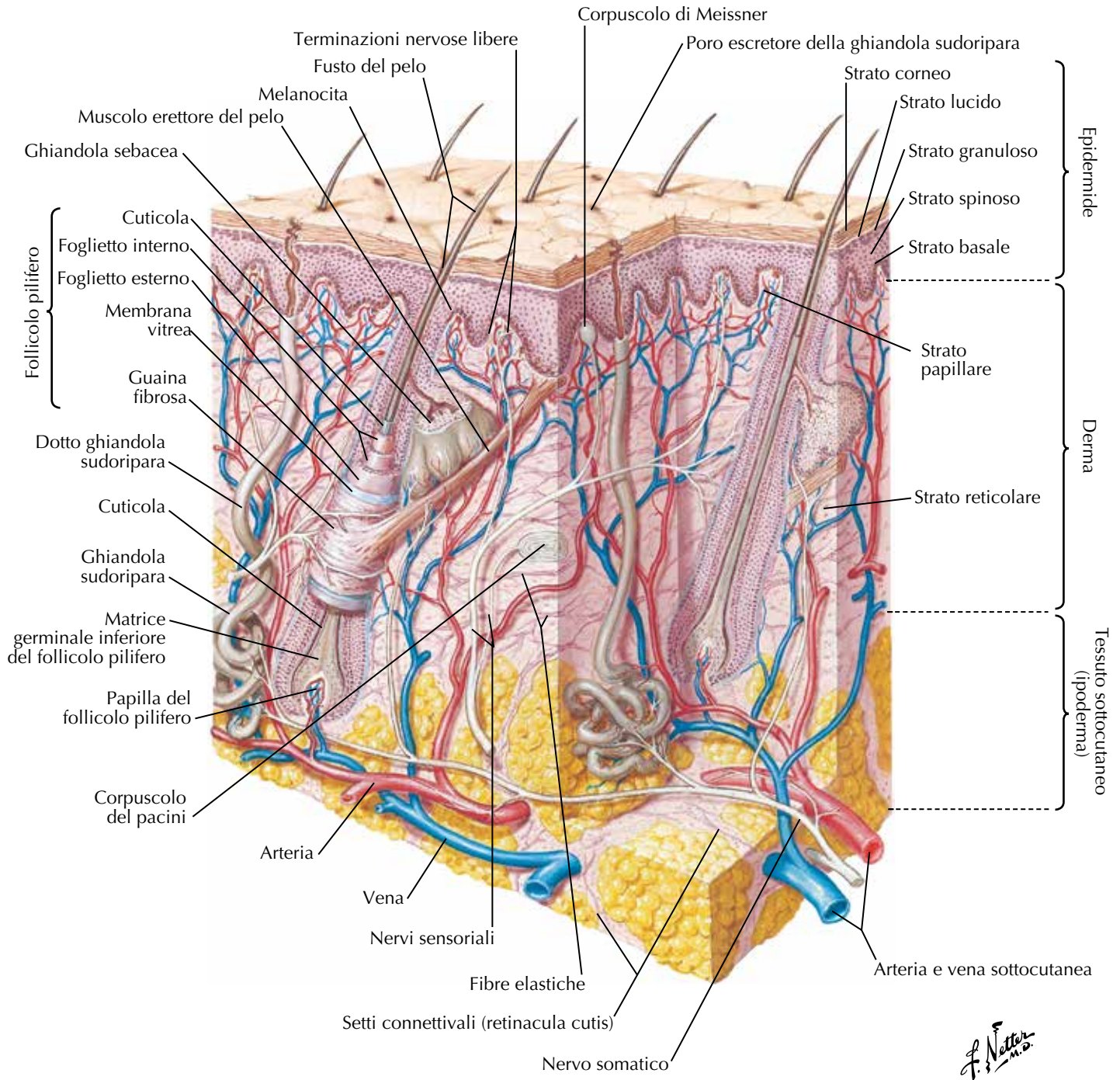
Innervazione segmentaria dei movimenti dell'arto inferiore





Sezione trasversale della cute

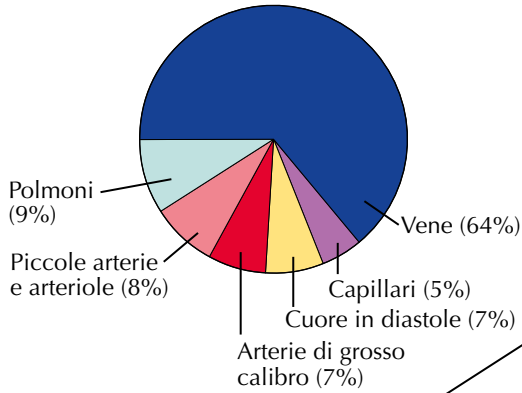
Vedi anche **Tavola TB 1**



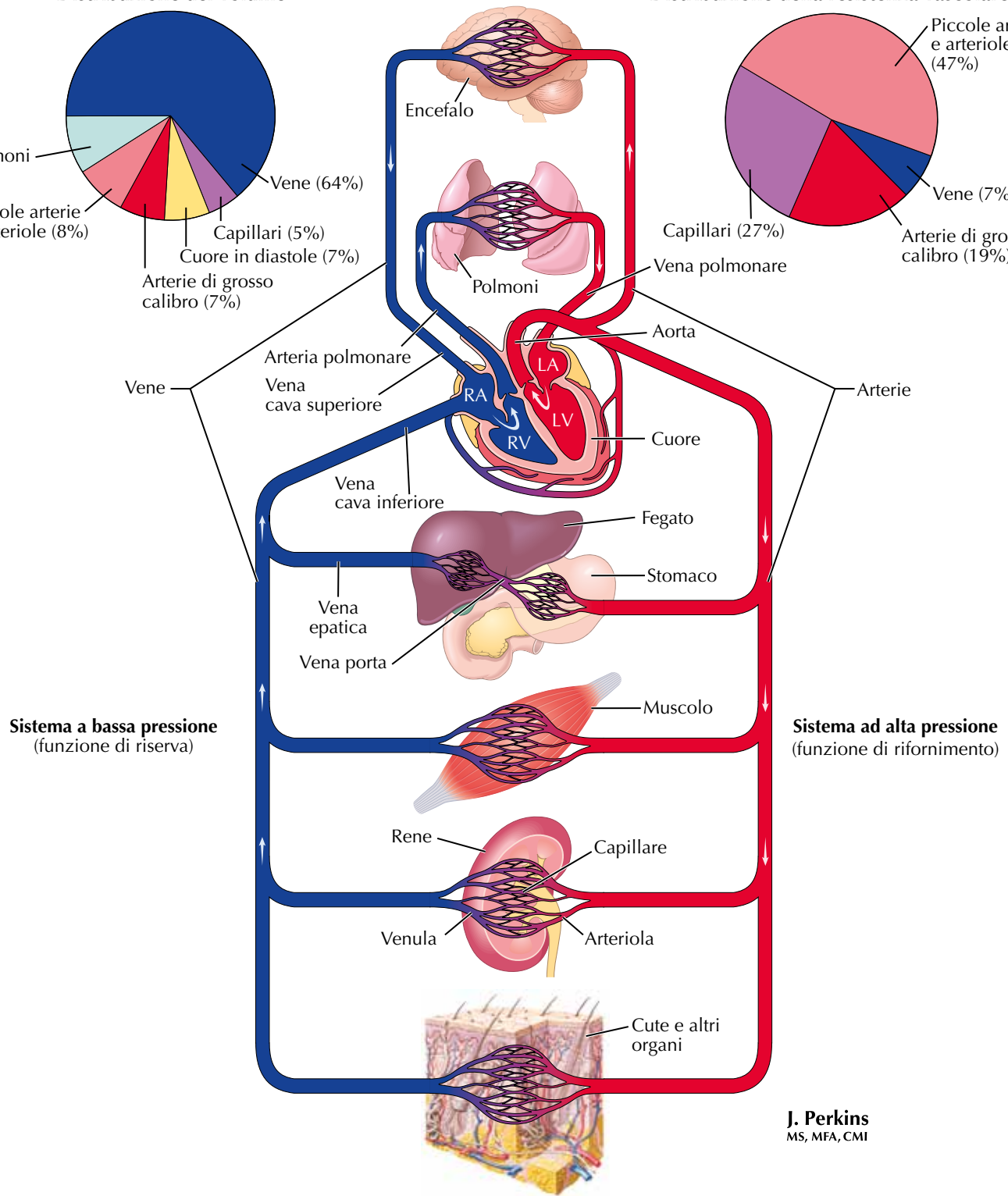
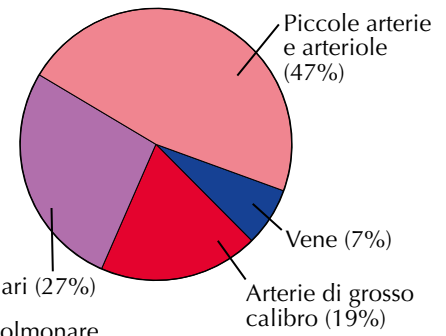
F. Netter M.D.



Distribuzione del volume



Distribuzione della resistenza vascolare

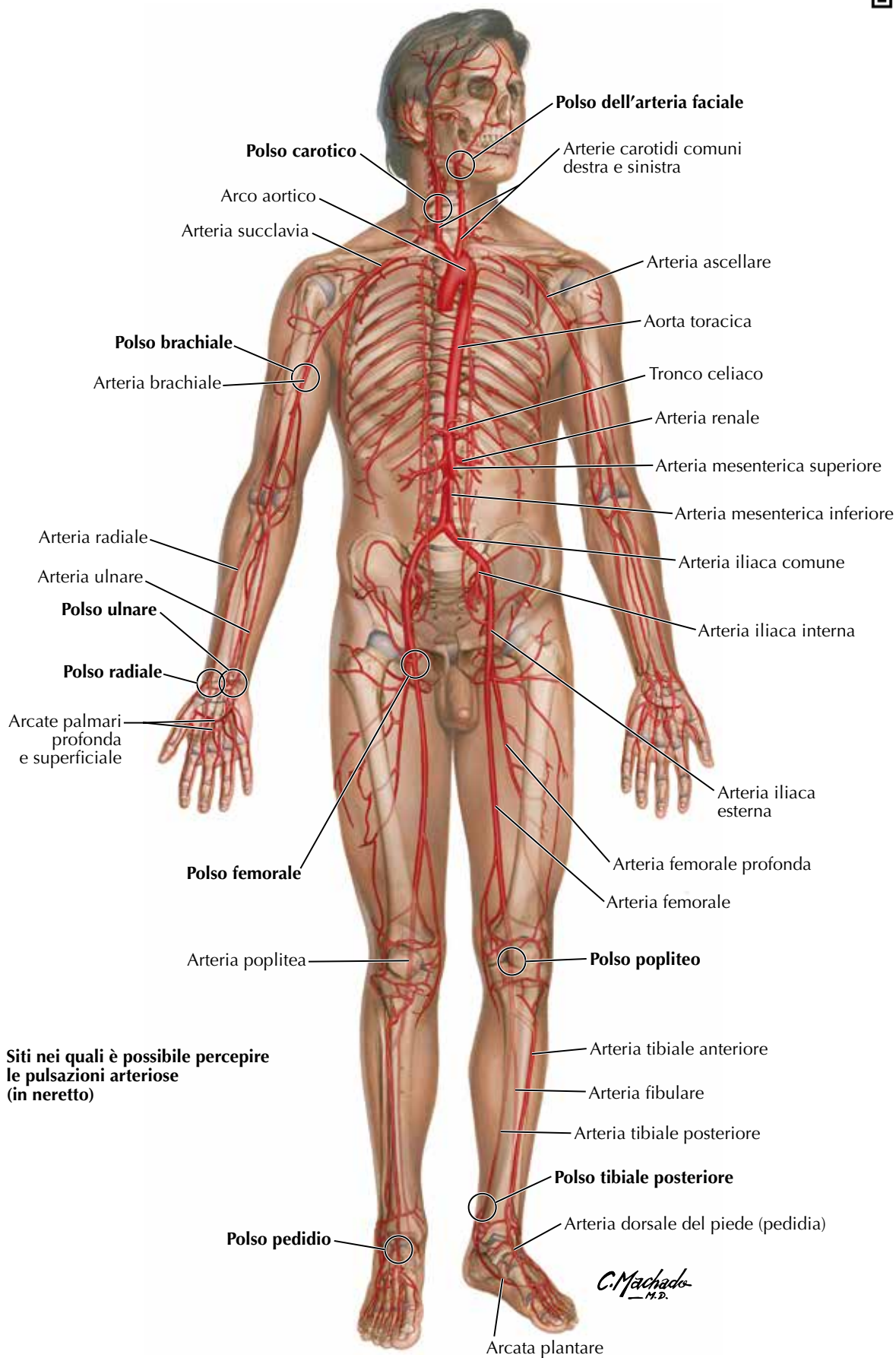


J. Perkins
MS, MFA, CMI



Principali arterie e siti di rilievo dei relativi polsi

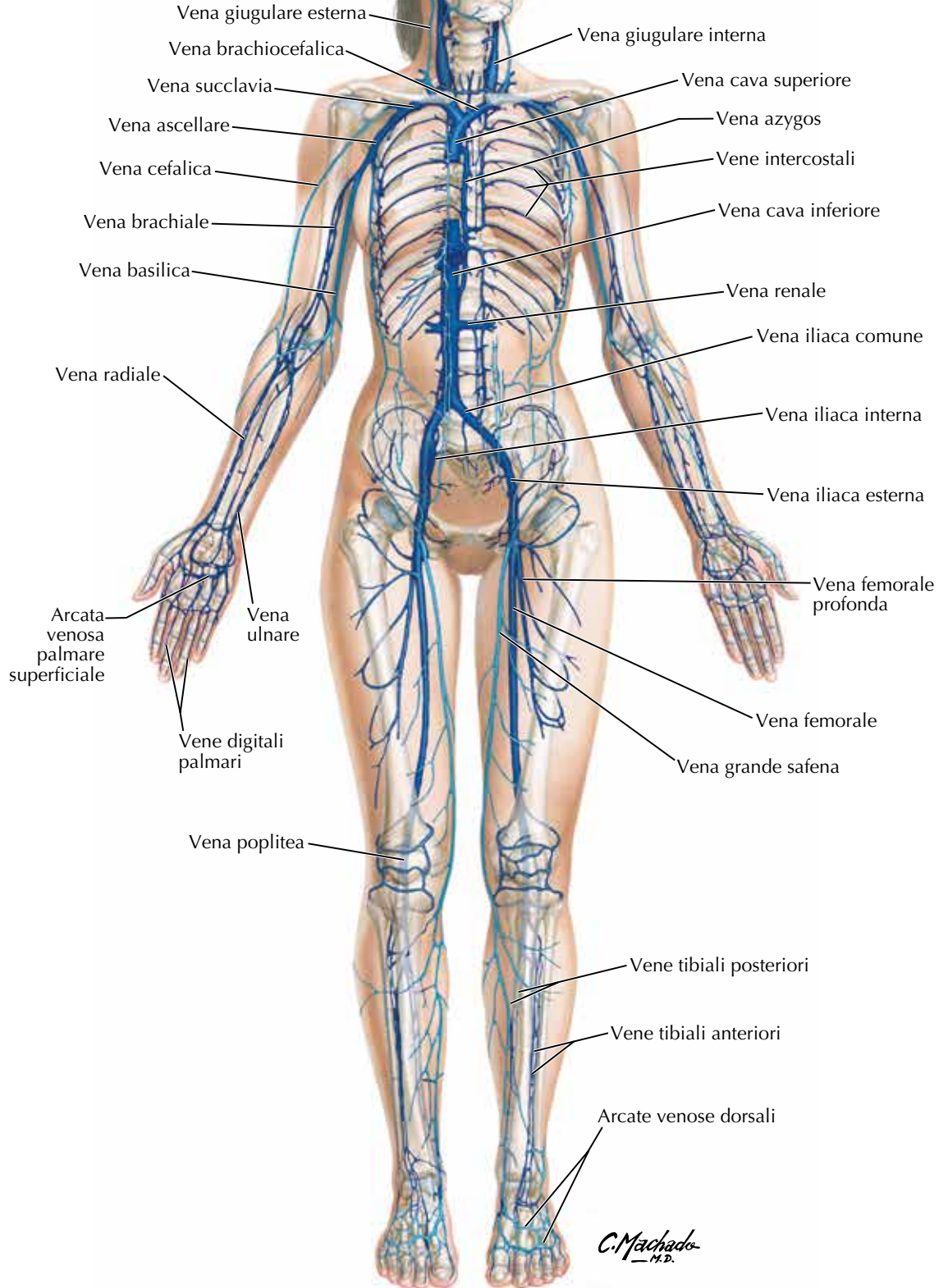
Vedi anche **Tavola TB 13**



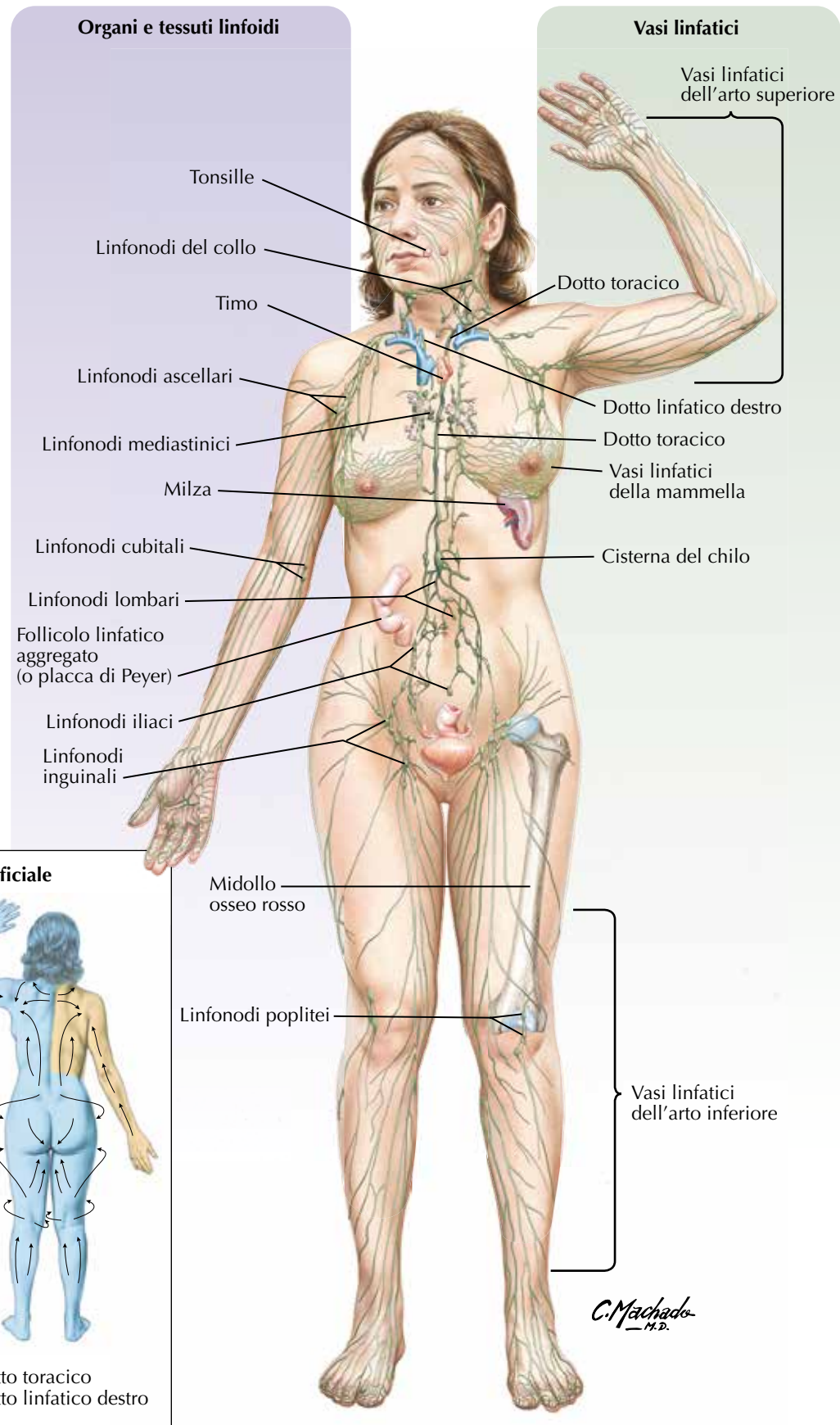


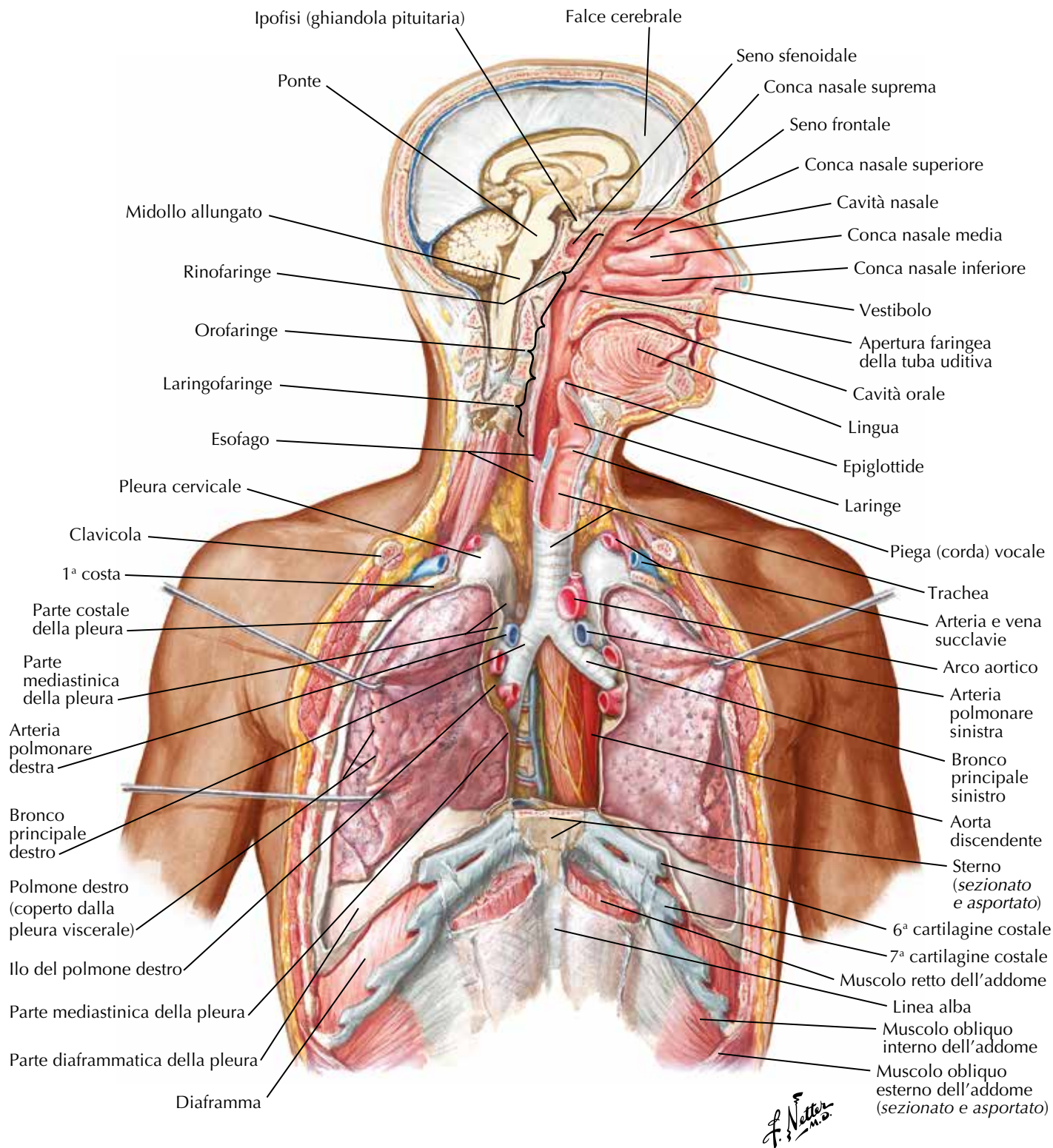
Principali vene

- Vene superficiali
- Vene profonde



C. Machado
—M.D.

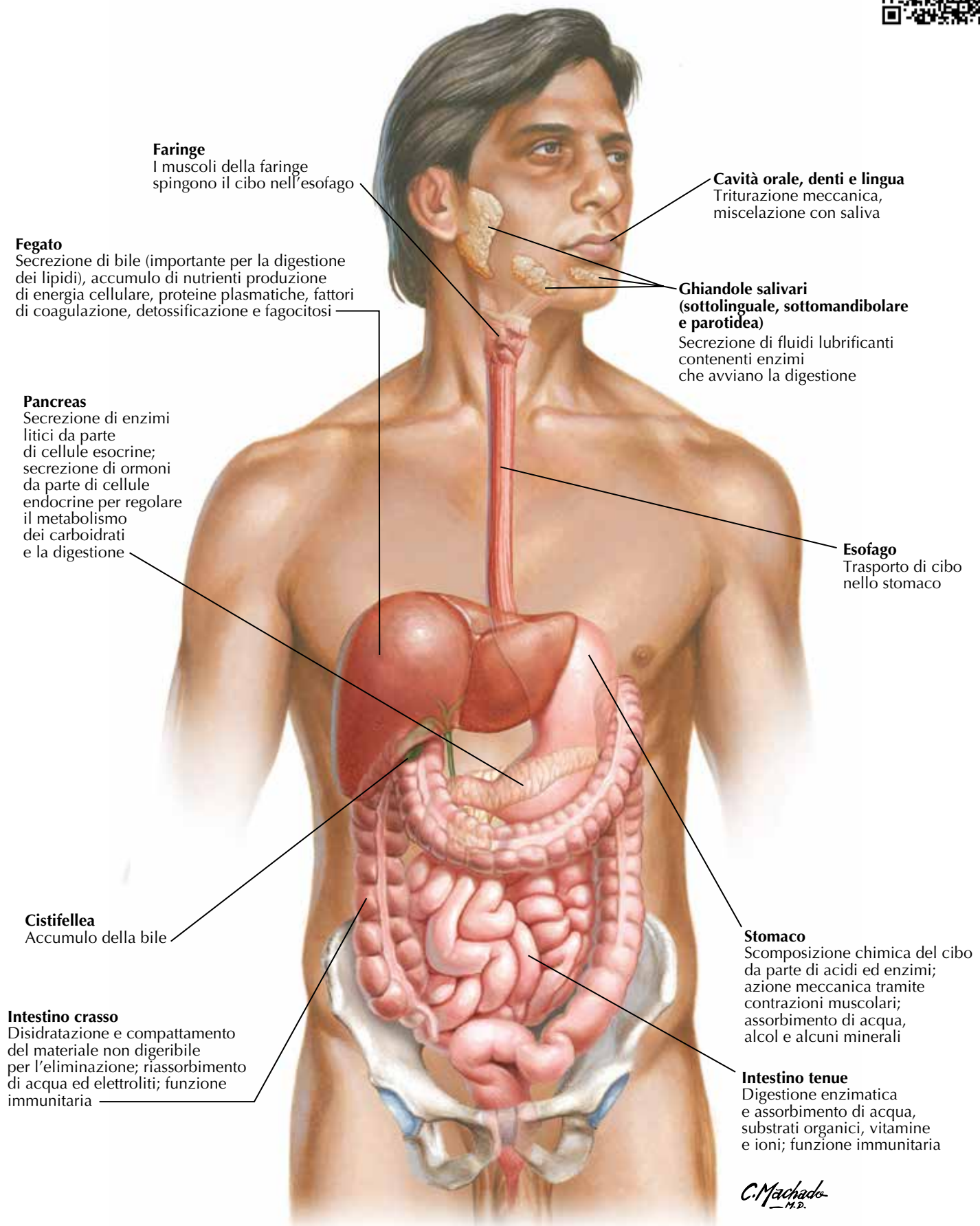


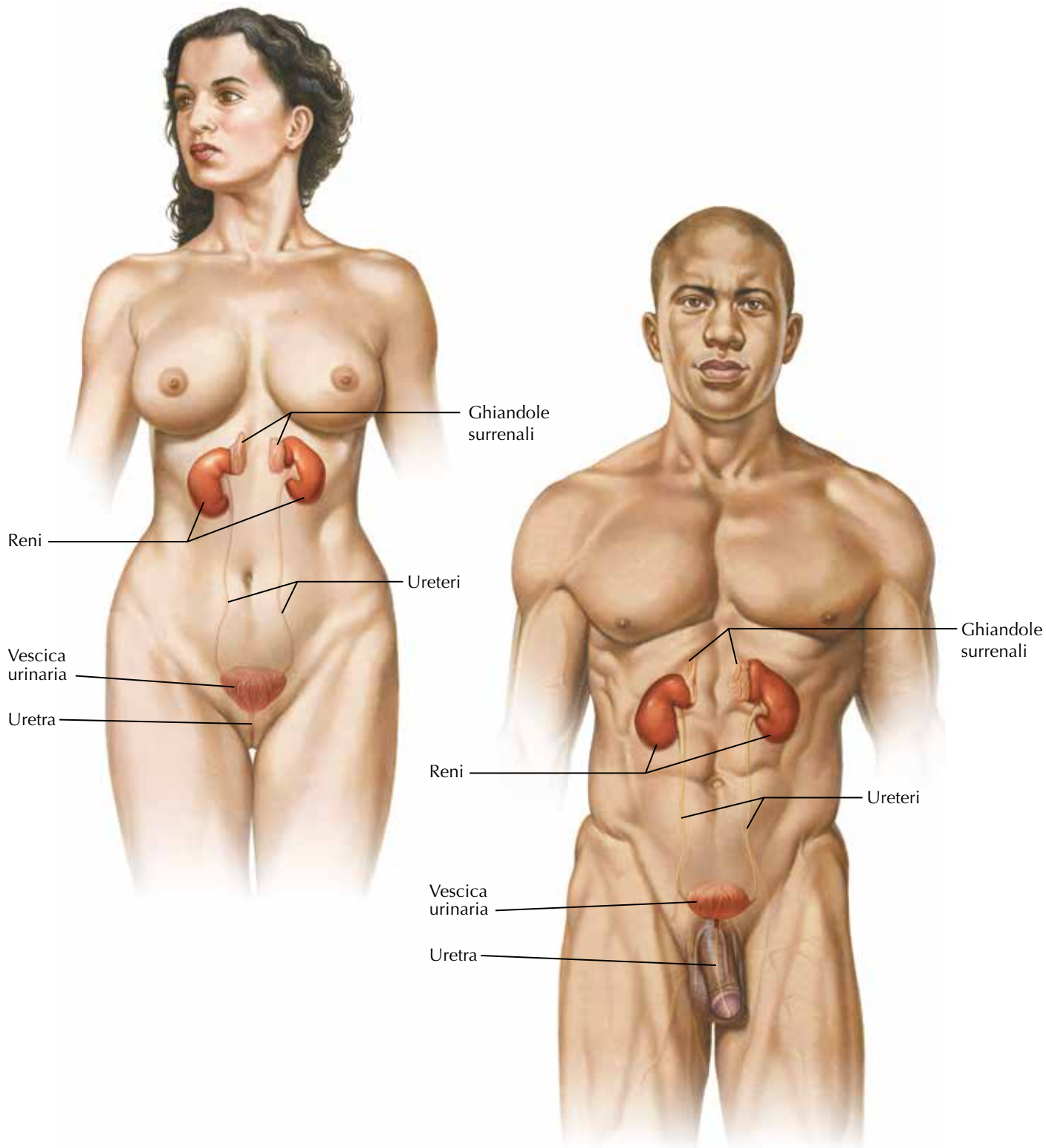


F. Netter M.D.

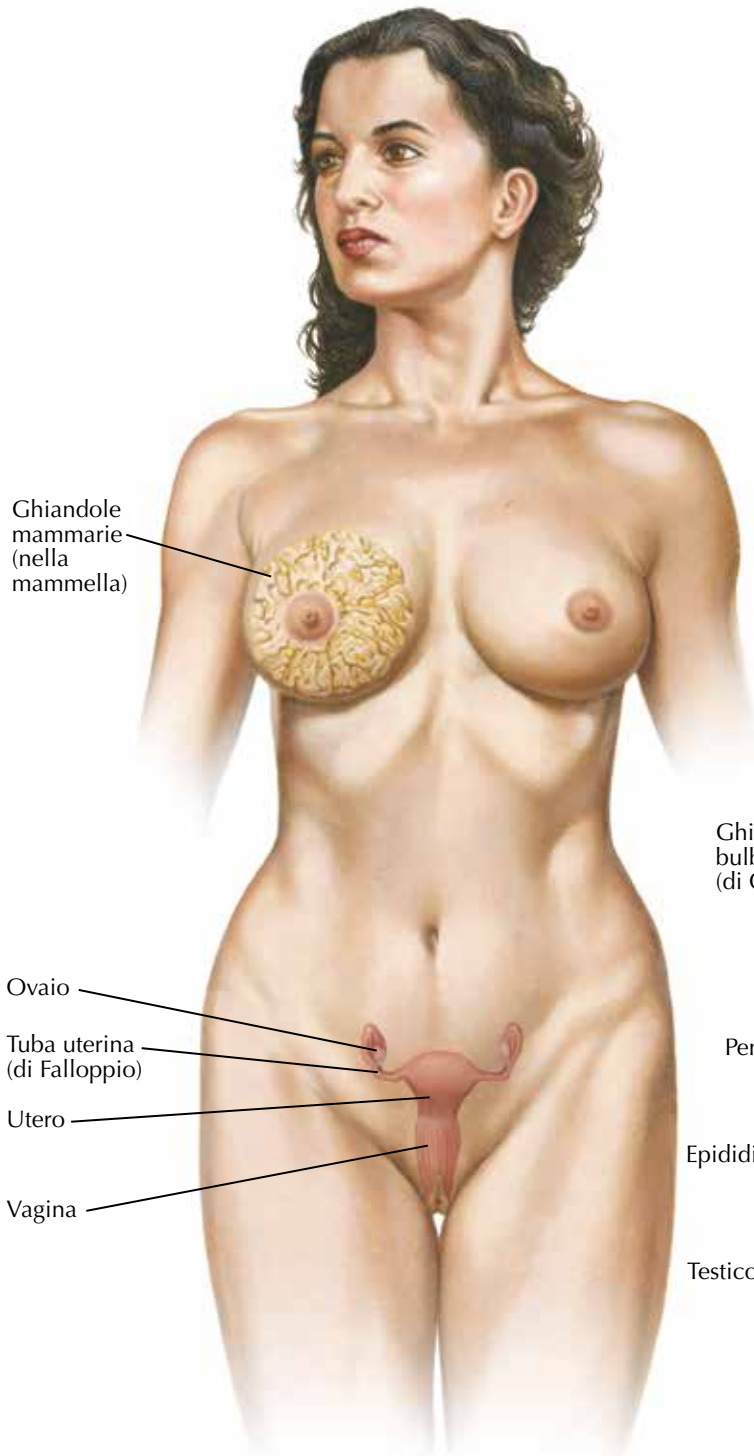


Panoramica del sistema gastrointestinale





C. Machado
M.D.



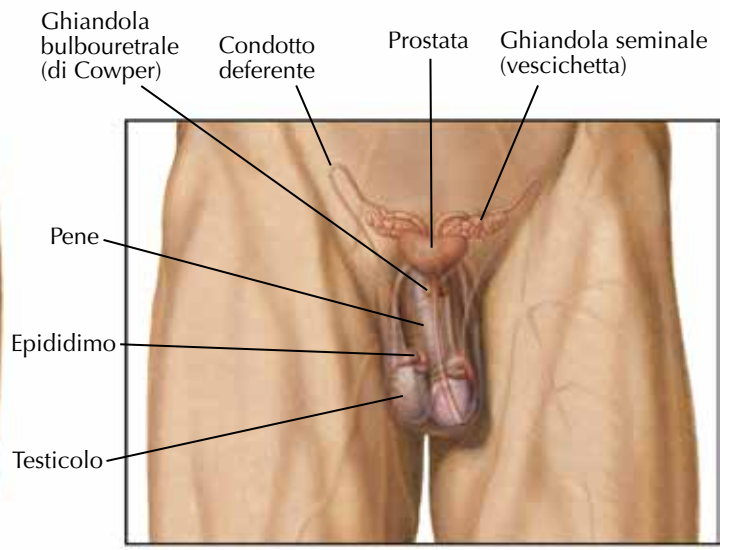
Ghiandole mammarie (nella mammella)

Ovaio

Tuba uterina (di Falloppio)

Utero

Vagina



Ghiandola bulbouretrale (di Cowper)

Condotto deferente

Prostata

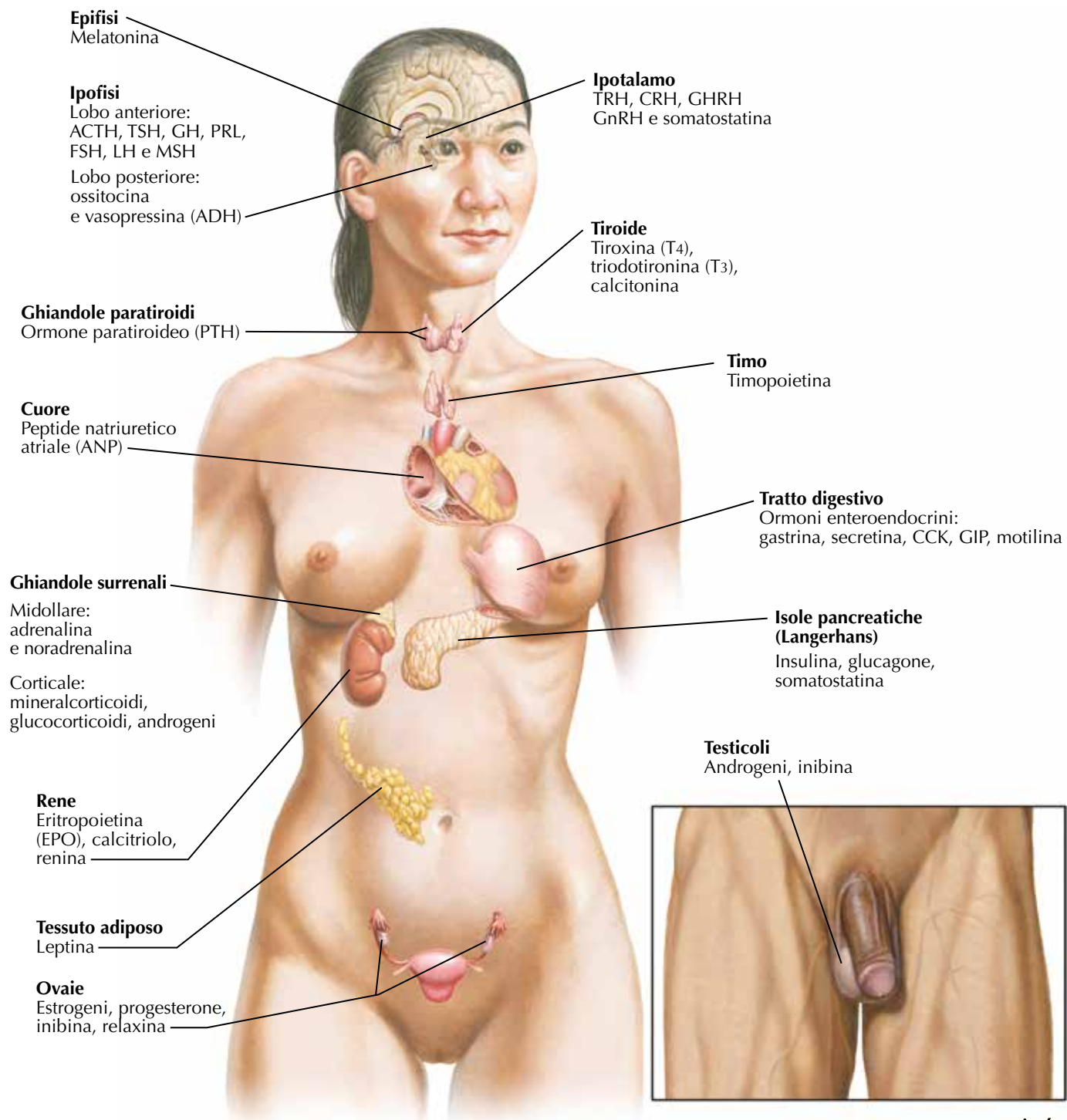
Ghiandola seminale (vescichetta)

Pene

Epididimo

Testicolo

C. Machado M.D.



C. Machado
—M.D.